REPORT DOCUMENTATION PAGE

Form Approved
OMB No. 0704-0188

Public reporting burden for this collection of information is estimated to average 1 hour per response, including the time for reviewing instructions, searching existing data sources, gathering and maintaining the data needed, and completing and reviewing the collection of information. Send comments regarding this burden estimate or any other aspect of this collection of information, including suggestions for reducing this burden, to Washington Headquarters Services, Directorate for Information Operations and Reports, 1215 Jefferson Davis Highway, Suite 1204, Arlington, VA 22202-4302, and to the Office of Management and Budget, Paperwork Reduction Project (0704-0188), Washington, DC 20503.

1. AGENCY USE ONLY *(Leave blank)*

2. REPORT DATE
31.Jan.03

3. REPORT TYPE AND DATES COVERED
THESIS

4. TITLE AND SUBTITLE
JPEF 2000 COMPRESSION OF DIRECT DIGITAL IMAGES: EFFECTS ON THE DETECTION OF PERIAPICAL RADIOLUCENCIES AND PERCEIVED IMAGE QUEALITY

5. FUNDING NUMBERS

6. AUTHOR(S)
MAJ MASSEY MARK A

7. PERFORMING ORGANIZATION NAME(S) AND ADDRESS(ES)
INDIANA UNIVERSITY PURDUE INDIANAPOLIS

8. PERFORMING ORGANIZATION REPORT NUMBER
CI02-843

9. SPONSORING/MONITORING AGENCY NAME(S) AND ADDRESS(ES)
THE DEPARTMENT OF THE AIR FORCE
AFIT/CIA, BLDG 125
2950 P STREET
WPAFB OH 45433

10. SPONSORING/MONITORING AGENCY REPORT NUMBER

11. SUPPLEMENTARY NOTES

12a. DISTRIBUTION AVAILABILITY STATEMENT
Unlimited distribution
In Accordance With AFI 35-205/AFIT Sup 1

12b. DISTRIBUTION CODE

13. ABSTRACT *(Maximum 200 words)*

DISTRIBUTION STATEMENT A
Approved for Public Release
Distribution Unlimited

20030221 170

14. SUBJECT TERMS

15. NUMBER OF PAGES
93

16. PRICE CODE

17. SECURITY CLASSIFICATION OF REPORT

18. SECURITY CLASSIFICATION OF THIS PAGE

19. SECURITY CLASSIFICATION OF ABSTRACT

20. LIMITATION OF ABSTRACT

The views expressed in this article are those of the author and do not reflect the official policy of position of the United States Air Force, Department of Defense, of the U.S. Government.

JPEG 2000 COMPRESSION OF DIRECT DIGITAL IMAGES: EFFECTS ON THE DETECTION OF PERIAPICAL RADIOLUCENCIES AND PERCEIVED IMAGE QUALITY

by

Mark A. Massey

Submitted to the Graduate Faculty of the School of Dentistry in partial fulfillment of the requirements for the degree of Master of Science in Dentistry, Indiana University School of Dentistry, 2002.

Thesis accepted by the faculty of the Department of Endodontics, Indiana University School of Dentistry, in partial fulfillment of the requirements for the degree of Master of Science in Dentistry.

Edwin T. Parks

Joseph J. Legan

Phil P. Guba

Susan L. Zunt

Kenneth J. Spolnik

Cecil E. Brown
Chair of the Committee

Date June 31, 2002

ACKNOWLEDGMENTS

I would like to express my sincere appreciation to Dr. Cecil Brown, of Graduate Endodontics, for giving me the opportunity to further my education in the field of endodontics. He has been both a mentor and a friend and provided a great learning environment.

I would like to thank Dr. Phil Guba for all the time and effort he has put forth in helping me complete this research project. His advice and editing were invaluable.

I would like to thank the other members of my research committee, Drs. Edwin T. Parks, Joseph J. Legan, Susan L. Zunt and Kenneth J. Spolnik. It has been a privilege to know them and have them serve on my committee.

A special thanks goes to all the part-time faculty members that have so generously given their time and expertise to better our education: Drs. William Adams, Kenneth Spolnik, Kevin Deardorf, Carl Newton, Charles Steffel, Doug Ramsey, Beverly Leddy, and Michael Keller.

The hard work of Karen Bissonette, Sara Rentsch, and Elaine May will always be remembered. You always made me feel like part of the family, and your dedication to the program and patients made the clinic a great learning environment.

I am grateful to Joanne Fyffe for her efforts with the statistical analysis portion of this thesis. The Dental Illustrations team of Tom Meadors and Amanda Marlett was always helpful, and their efforts are greatly appreciated. I would also like to thank Ben Adams for his exhaustive efforts in literature review.

Special thanks and best wishes to my fellow residents: Drs. Michael Gideon, Scott Risser, Krie Brasseale, Joseph Spires, Cliff Fiscus, Sean Hart, and Cary Orton. I could not have hoped for better classmates and feel blessed to have known each of you.

Lastly, I would like to thank my wonderful family, to whom I have dedicated this thesis. Because of the love, support, and sacrifices of my beautiful wife, [redacted] I have been able to accomplish my professional goals. Thanks to [redacted], and [redacted] for enduring all my studying when we could have been playing. Thank you to my parents, [redacted]; I have been blessed to have your encouragement, love, and support throughout the years.

TABLE OF CONTENTS

Introduction.....1

Review of Literature.....4

Methods and Materials.....44

Results.....48

Tables and Figures.....52

Discussion.....73

Summary and Conclusions.....78

References.....82

Abstract.....91

Curriculum Vitae

LIST OF ILLUSTRATIONS

TABLE I Overall inta-examiner agreement in determining presence of a lesion.....53

TABLE II Intra-examiner agreement of presence of a lesion for each level of compression.....54

TABLE III Inter-examiner agreement in determining presence of a lesion at each level of compression.....55

TABLE IV Examiner response in determining presence of a lesion expressed as a percentage using the lesion presence scale.....56

TABLE V Overall intra-examiner agreement in determining image quality..57

TABLE VI Intra-examiner agreement of image quality for each level of compression.....58

TABLE VII Inter-examiner agreement in determining image quality at each level of compression.....59

FIGURE 1 Screen display used for image evaluation.....60

FIGURE 2 Lesion size determined by greatest diameter.....61

FIGURE 3 Test image with no periapical radiolucency associated with root identified by digital marker.....62

FIGURE 4 Test image with periapical lesion 0.1 mm to 2.0 mm greatest diameter associated with root identified by digital marker.....63

FIGURE 5 Test image with periapical lesion 2.1 mm to 4.0 mm greatest diameter associated with root identified by digital marker.....64

FIGURE 6 Test image with periapical lesion greater than 4.0 mm greatest diameter associated with root identified by digital marker.....65

FIGURE 7 Images were viewed under dark room conditions on a 17-inch cathode ray tube monitor, COMPAQ QVISION 210.....66

FIGURE 8 Test image with compression ratio of 1:1.....67

FIGURE 9 Test image with compression ratio of 1:8.....68

FIGURE 10 Test image with compression ratio of 1:20.....69

FIGURE 11 Test image with compression ratio of 1:40.....70

FIGURE 12 Test image with compression ratio of 1:60.....71

FIGURE 13 Test image with compression ratio of 1:80.....72

INTRODUCTION

Radiographic evaluation is an essential component of endodontic diagnosis. In recent years, direct digital imaging (DDI) has been introduced to replace or augment radiographic film. Studies comparing diagnostic accuracy of DDI and conventional film for detection of artificially created periapical lesions have revealed comparable results.[1,2,3,4] Advantages of DDI have been reported as: 1) lower radiation exposure to patients, 2) elimination of chemical processing, 3) computer storage capability, 4) electronic transportation of images[5] and 5) instantaneous capture of images.

One disadvantage of DDI is the number of bytes required for storage. Data compression techniques are being developed to address this problem, but significant image deterioration can occur at high compression ratios.[6] The Joint Photographic Expert Group (JPEG) standard is the method of compression agreed upon in the medical field to archive and transport images.

JPEG is quite lossy in that the retrieved image is not identical to the saved or original image.[7] The selected algorithm is based on Discrete Cosine Transform (DCT) and achieves much of its compression by exploiting known limitations of the human eye. Acceptable compression ratios for images unique to dentistry need to be defined.

The purpose of this study was to ascertain the level of JPEG 2000 compression that significantly compromised an evaluators' ability to detect the presence of periapical radiolucencies of varied size. The perceived quality of the image was also evaluated.

The hypothesis of this study was that 1) as compression ratios increased, the determination of the presence or absence of a periapical lesion would become less

reliable; 2) lesions of smaller size would be more difficult to detect, and 3) perceived image quality would deteriorate. The null hypothesis stated that compression ratio and size of lesion would have no effect on the detection of the presence or absence of periapical lesions and perceived image quality.

REVIEW OF LITERATURE

HISTORY OF DENTAL RADIOGRAPHY

Willhelm Conrad Roentgen, a prominent experimental physicist in Wurzberg, Germany used a Hittorf-Crookes tube to make the first radiograph. Investigating cathode ray effects on November 8, 1895, he placed his wife's hand between the tube and a photographic plate for 15 minutes. On the developed plate the bone of her hand appeared light within the darker image of the flesh. For his work Roentgen received the Nobel Prize in 1901.[8]

Glenner[8] in 1975 discussed some of the highlights in dental radiography since Roentgen's discovery in 1895. Radiography was first used in dentistry in the removal of impacted and fractured teeth. The radiograph was made with a glass plate and 20-minute exposure time. On April 24, 1896, William James described the radiographic apparatus and displayed radiographs of restorations and crowns at a special meeting of the New York Odontological Society. He concluded that "the x-ray more than rivals your exploring mirror, your probe, your most delicate sense of touch, and your keenest powers of hypothetical diagnosis." C. Edmund Kells gave the first clinic on the use of the x-ray for dental purposes at the annual meeting of the Southern Dental Association at Asheville, NC. Dr. Kells was also the first to report the use of radiography in root canal therapy. Weston A. Price, in February 1900 called attention to incomplete root canal fillings as witnessed in radiographs. He reported in June 1901 that radiographs should be used to check the adequacy of root canal fillings.[8]

An important advancement in the field occurred in 1910 when Dr. Howard Riley Raper introduced dental radiography into the curriculum of the Indiana Dental School. Dr. Raper wrote the first text on dental radiography in 1913, and in 1924 he invented the bite-wing film. Dr. Raper reported in 1913 that 15 colleges were offering a course in radiography and that others incorporated the subject in other courses.[8]

Increased use of radiography in dentistry necessitated the standardization of technique. McCormack[9] in 1920 offered one of the early attempts at a standardized, reproducible technique. He outlined a method of patient positioning, film positioning, exposure, and film processing. Price and Cieszynski in the early 1900s developed the bisecting angle technique.[10] This method involved directing the central ray perpendicular to an imaginary plane between the film and the tooth. The technique is not reproducible and produces image distortion. LeMaster[11] in 1921 recommended the use of cotton rolls attached to the tube side of the film as an aid in achieving a parallel relation between the central beam and the film.

Because "pulpless teeth do not always remain the same," Liebman[12] in 1936 recommended the use of preoperative, postoperative, and recall radiographs. Sweet[13] in 1938 discussed the legal aspects of radiographs in dentistry. He reported that because of the universal availability of x-ray equipment, courts demand that dentists use radiographs.

ANATOMY AND PATHOSIS

Two types of bone may be distinguished in the mandible and maxilla: dense or compact bone (cortical plate) forming the vestibular and oral plates of the alveolar process, and the spongy or cancellous bone, which is the bone between the cortical plates and the alveolar bone proper. The lamina dura consists of the portion of bone adjacent to the periodontal membrane lining the socket. Spongy and compact types of bone do not represent histologically different types of osseous tissue. Spongy bone has a higher degree of porosity with the bony matter made up of trabeculae. Compact bone has some porosity, but the bony tissue is more densely packed and channels are small. Trabeculae in the spongy bone are joined to the lamina dura and to the cortical plates. Trabeculae show a parallel horizontal arrangement, which seems to be fairly consistent around the roots of teeth.[14]

Bender and Seltzer in 1961[15] discussed their radiographic and direct observation of mandibles from human cadavers. It was observed that the teeth were encased completely in lamina dura that joined with the outer cortex. Being composed of cortical bone, the lamina dura has a junction area in contact with trabeculae. The presence of lamina dura accounts for the increase in trabeculae found in dentigerous regions, especially between teeth and towards the alveolar ridge.

A radiographic study of human mandibular and maxillary dried bone specimens revealed that removal of the buccal and lingual alveolar plates did not affect the trabecular pattern in radiographs. The compact bone is dense and has very little architectural pattern. The lingual and buccal alveolar plates affect the density of the radiograph depending on their thickness.[14]

Lamina dura appears radiographically as a thin opaque line due to the shape of the tooth socket. The x-rays are not passing through a single width of alveolar bone proper but many times its width. The lamina dura registration results from the presence of dense bone extending the bucco-lingual width of the tooth. It is the quantity, not the character of bone that determines radiographic findings. This also explains the appearance of the inferior border of the mandible and the alveolar crest.[14]

Manson[16] in 1963 reported on a microradiographic study of the tooth socket wall in 17 specimens of human mandible. Sections were cut 60 μm to 80 μm thick and microradiographs were taken. Results indicated: 1) the white line on the dental radiograph usually reflects a plate of bone that lines the tooth socket and through which the x-rays must pass tangentially, through a greater thickness of bone than the actual width of the alveolar plate with resulting attenuation of the x-rays. The appearance of the line is determined as much by the shape and position of the tooth root in relation to the x-ray beam as by the integrity of the plate of bone; 2) the bone of the socket wall has the same mineral content as neighboring bone, and there is no evidence of a special bone tissue with a higher mineral content, and 3) a similar white line can be produced as an artifact. It is for these reasons the evaluator recommended avoiding too critical an interpretation of the lamina dura and not to allow variations in its appearance to determine diagnosis or treatment.

The appearance of the lamina dura in radiographs of a dried human mandible and radiographs of plastic cubes of different shapes were evaluated and compared by Kilpinen and Hakala[17] in 1978. Visual interpretations of the radiographs were compared with curves recorded microdensitometrically. "The observations indicated that, 1) an

opaque shadow seen on the boundary between two zones of differing densities is an optical artifact and that 2) the lamina dura is not one of these optical artifacts. Its visibility is due to the direction of the roentgen rays, the shape of the alveolus and the higher mineral content of the alveolar wall compared to the rest of the alveolar bone."

In 1950 Ingram[18] detailed the mechanisms by which a tooth becomes necrotic. After the infection passes through the apical foramen the bone around the apex will show resorption or rarefaction radiographically. The lamina dura near the apex will become thinner with consequent widening of the periodontal membrane. Ingram[18] concluded that the lamina dura must be disrupted together with a dark shadow around the apex for the area to be described as a periapical radiolucency. If the lamina dura remains intact, then any radiolucent area around the apex must be considered a variation of normal or pathosis of non-endodontic origin.

Hutchinson[19] described how pulpal inflammation will obliterate the trabeculae as it spreads through cancellous bone resulting in a radiolucency around the apex of the tooth. In 1958 Stafne[20] confirmed that inflammation and necrosis of the dental pulp are the most common causes of periapical infections, and that widening of the periodontal membrane space is the earliest radiographic evidence. Ennis[21] explained bacteria may enter the apical region by passing from the coronal aspect of the tooth and through the root canal space or from other parts of the body by a hematologic route. Ennis[21] assumed that the radiolucencies represent granulomas. Kakehashi et al.[22] by exposing the pulps of conventional and germ-free rats conclusively determined that bacteria are necessary for pulpal and periapical pathosis.

The periapical granuloma is a localized mass of chronic inflammatory tissue that forms in response to infection of the dental pulp. The granuloma is initiated in the periodontal ligament and enlarges at the expense of bone supporting the tooth. Predominant cells in the periapical inflammatory lesions are T-lymphocytes and macrophages. Foreign body giant cells are found in periapical granulomas in which cholesterol crystals have accumulated. Fibroblasts and bundles of collagen are often found at the periphery of the lesion, often in a capsular arrangement. The presence of epithelium is common arising from the epithelial rests of Malassez. Epithelial proliferation may in time result in formation of a cyst.[23]

Eberhard and Plagmann[24] in 1999 studied 64 root surfaces using light microscopic morphometrical procedures to evaluate changes in the periodontal membrane due to apical periodontitis. The histological material consisted of 16 teeth with periapical granulomas that were extracted due to deep dental caries. Attachment was lost apically. Principal fibers running to the root surface as well as extensions in the cementum decreased from the coronal to the apical direction. They were replaced by fibers running parallel to the cementum and by fibers arranged in a network. The authors suggested acellular extrinsic fiber cementum was lost and that cellular mixed stratified cementum was laid down. Changes are suspected to be the result of the anti-inflammatory reaction caused by the periapical lesion.

Lin et al.[25] in 2000 exposed the pulp chamber of the right mandibular first molars of Wistar rats to the oral environment to induce apical periodontitis. Lesions expanded in a time-dependent manner from day 0 to day 20 (active phase). Lesions stabilized thereafter (chronic phase). Transforming growth factor (TGF) -$Beta_1$ positive

macrophages were found in areas of active resorption. TGF-Beta$_1$ positive osteoblasts were also detected during the chronic stage. The investigators suggested macrophages plan an important role in the initiation, and that the development of periapical lesions and TGF-Beta$_1$ may play dual roles in both bone resorption and deposition in induced rat periapical lesions.

The profile of glycosphingolipids (GSLs) in periradicular lesions refractory to endodontic treatment was analyzed by Zuolo et al.[26] in 2001. Sixteen periapical lesions (experimental group) were removed surgically and compared with 10 samples of periodontal ligament from extracted third molars (control group). Tissues in the experimental group contained twice the level of GSLs as the control. Lesional tissues expressed lactoneotetraosylceramide and lactofucopentaosyl (IV) ceramide, which are absent in normal tissues. Normal tissues express GT1$_b$, which is not expressed in lesional cells. Lesional cells also express GM3, which is absent in normal tissues. The authors concluded it is difficult to evaluate the biological significance of GSL metabolism change in lesion cells at the present time.

RADIOGRAPHIC DETECTION OF PERIRADICULAR PATHOSIS

Radiographic changes appear sooner in some teeth with periapical inflammation than in other teeth. The changes are dependent upon the position of the apices in relation to the cortical plate.[27] The closer the root apex is to the cortex, the sooner the radiographic detection occurs. The mesial root of a mandibular first molar, for example, will have a detectable periapical lesion before the distal root, which is more centrally located within the mandible.

When a radiolucent lesion is seen on a radiograph, neither the extent of the buccolingual area, nor whether one or both cortical plates are involved can be determined.[14] This is more apparent in the maxilla than the mandible, because of the thinner cortical plates. A part of the cortical plate can be missing without any change in appearance of the radiograph due to masking from the trabecular pattern of spongy bone. When roots are denuded of bone in the apical third, the condition is also undetectable radiographically.[15]

The effects of the depth of lesions in the cortical bone of mandibles of human cadavers were evaluated by Bender and Seltzer.[15] Holes were drilled with round burs of various sizes to depths of 1 mm, halfway into the buccal cortex, through the buccal cortex, and deep enough to penetrate both buccal and lingual cortical plates. Lesions 1 mm in depth were not detectable radiographically, regardless of the size of bur used. As the depth of the defect increased, the rarefaction became more pronounced and more readily observed. Radiographic evidence alone is not sufficient to determine whether the lesion involves the buccal or lingual cortical plate.[15]

A fissure bur was used by Ramadan and Mitchell[28] in 1962 to produce bone defects simulating the effects of pathoses on one human dry skull and mandible. Under the conditions of the experiment, it was found that: 1) minor destructive changes in the alveolar crest could not be detected by radiographs; 2) destruction of the buccal alveolar crest could not be distinguished from destruction of the lingual alveolar crest; 3) funnel-shaped destruction of the alveolar crest leaving outer and inner alveolar plates intact did not register on the film; (4) a reliable method for obtaining a good radiograph of the alveolar crest is to align the long axis of the tooth parallel to the film with the central

beam directed at right angles to the film; (5) removal of the entire buccal or lingual plate did not alter the architectural pattern of bone in the radiograph; (6) bone destruction caused by a periodontal abscess or any localized periodontal disease in many cases would not show if the defect was superimposed by the roots, especially if cortical plates of bone were thin; (7) removal of the central trabeculae in the mandible and maxilla, leaving the junctional trabeculae intact, did not affect the trabecular pattern; (8) removal of the junctional trabeculae of the maxilla, leaving the central trabeculae intact, did not alter the trabecular pattern; and (9) removal of both types of trabeculae affected the architectural pattern.

In mandibles of human cadavers, cancellous bone was removed until there was a complete hollow within bone. Radiographic examination failed to show a radiolucency or changes in the trabecular pattern of bone. When a bur eroded the innermost surface of the bone cortex, a distinct radiolucent shadow appeared. Changes are detectable only if there is encroachment on the innermost surface of the cortical bone, or if there is a perforation.[15]

A radiographic survey of mandibles and maxilla of 57 human cadavers was done to locate bone pathoses by Regan and Mitchell in 1963.[29] In 289 teeth, 18 radiolucencies were detected. A comparison was made between the radiographic findings and the morphology of the bone destruction. The buccal plate was perforated in 14 of the 18 lesions, although this could not be detected by the radiograph alone. The thickness of remaining cortical plate in nonperforating lesions was reduced to less than 1 mm. The size of the radiolucency did not necessarily indicate the presence or absence of cortical

bone. The amount of bone destruction could not accurately be determined from radiographs.

An investigation by Brynolf[30] in 1970 based on radiographs of 212 upper incisors compared radiographic findings with the histological diagnosis. When interpretation was based on a single film, a correct diagnosis was made in 74 percent of cases. When radiographs were taken at three different angles, accuracy was improved to 90 percent. Histological specimens were obtained by removal of the apex and surrounding tissues immediately after radiographs were taken.

X-RAYS IN DENTISTRY

The x-ray beam is composed of electromagnetic radiation. X-rays transport energy through space in the form of electromagnetic waves that travel at the speed of light in a vacuum. Because x-rays do not always behave as waves but as particles (dual nature), it is convenient to describe them in terms of photons (discrete bundles of energy).[31]

Production of x-rays requires an x-ray tube and an x-ray generator. When activated, a low-voltage current flows through the cathode coil or filament. The tungsten filament is heated to a high temperature and ejects electrons forming an electron cloud. A second high-voltage current produces a large potential difference between the cathode and anode and accelerates the electrons in a unidirectional flow from the filament to the anode target. Electrons colliding with the target transform their kinetic energy into heat (99 percent) and x-rays (1 percent). The x-ray generator supplies constant electric power to the x-ray tube. The generator has a control panel containing milliamperage control, a

timer, and kilovoltage (kVp) control. The milliamperage control determines current flow to the cathode filament, determining the number of electrons produced and ultimately the number of x-rays generated. The kilovoltage control determines the potential difference across the x-ray tube influencing the maximum energy level or quality of electrons produced as well as quantity.[31]

During exposure of a dental radiograph, a patient will be exposed to a given amount of radiation. A single periapical radiograph (90 kVp, 15ma, 0.4 seconds at 16 inch focal skin distance, and 2.1-mm aluminum half-value layer) has an exposure level of 0.25 millirads.[32] Nolan[33] in 1953 found a higher skin radiation dose to patients during a full-mouth survey with 45 kVp compared with 65 kVp. He recommended reducing radiation by increasing the use of filtration and collimation. A skin-dose reduction of 21.5 percent when voltage was changed from 65 kVp to 90 kVp was shown by Richards[34] in 1964. Adding filtration, collimation, and faster film, he showed a skin-dose reduction of 89 percent. It was noted that while filtration provided more reduction, image contrast decreased dramatically, compromising diagnostic quality of the film.

A collimator is incorporated to limit the size of the x-ray beam to match the film size. It also contains an aluminum filter to absorb long-wave, low energy x-rays that will not penetrate to the film and would otherwise be absorbed by the patient. This acts to increase the mean x-ray energy of the primary beam.[31] Alcox and Jamison[35] in 1974 studied cone length and its effect on radiation exposure to patients. Increased-radiation skin dose was found with shorter cone lengths and lower kilovoltages. The cone length had only a small effect on total patient-absorbed dose as demonstrated by Welander and Wickman[36] in 1977.

X-ray beam intensity is dependent upon the focal spot to film distance. The beam loses intensity while moving away from its source. The inverse square law is a mathematical formula to determine new control settings for changes in source-to-object distance. Radiation intensity at a set distance from the source is inversely proportional to the square of the source-object distance. If the length of the cone is doubled with mA and kVp remaining constant, the exposure time must be quadrupled to expose the film to the same quantity of radiation.[37]

Exposure parameters are controlled by kilovoltage, milliamperes and time. Low kilovoltage results in x-rays of lower energy, which fail to penetrate to the film. High kilovoltage results in increased patient dosage and scatter, which deteriorates the quality of the film image. The range used in dental radiography is usually between 70 kVp and 90 kVp. The milliampere and time are directly proportional to the quantity of x-rays emitted. A measure of x-ray quantity has been devised, called milliampere-seconds (mAs), which is calculated by multiplying milliampers by exposure time in seconds. To reduce the chance of patient movement, it may be advantageous to select a shorter exposure time, e.g. the product of two-thirds second and 15 mA, as opposed to the product of one second and 10 mA.[31] The exposure parameters discussed determine the image produced by the sensor or x-ray film. The image characteristics are usually discussed as density, contrast, and resolution. The overall degree of darkening is referred to as density. Density is determined by the number of photons absorbed by the film or sensor. Increasing the milliamperage (mA), operating voltage (kVp), or exposure time will increase density. Radiographic contrast is the difference in densities between various regions on a radiograph. An image with high contrast would show very light

areas and very dark areas and is referred to as a short gray scale of contrast. There are few shades of gray between black and white images on the radiograph. The degree of contrast seen in an image is dependent on subject contrast, film contrast, beam energy and intensity, fog and scattered radiation. Resolution is the ability of an image to record separate structures that are close together. It is measured as the highest number of line pairs (thin lead strips) per millimeter that can be distinguished. Resolution is influenced by focal spot size, motion, and the image receptor.[10] Geometric unsharpness or diffusion of detail is controlled largely by three factors: the focal spot-film distance, the object-film distance, and the effective focal spot used in the x-ray tube. Fitzgerald in 1947, using two dried sections of mandible, made visual comparisons of resulting radiographs.[38] The smallest effective focal spot resulted in greater sharpness or detail.

All radiographs have some image distortion regardless of the technique used. The bisecting angle technique results in the most distortion when projecting three-dimensional objects onto a two-dimensional surface. Anatomic structures furthest from the film are projected at greater angulation than those in close proximity rendering more inherent dimensional distortion. The foreshortening of mesiobuccal and distobuccal roots of maxillary molars compared with the palatal root is a classic example.[39] Updegrave[40] in 1951 stated:

> To produce radiographs portraying the teeth and supporting structures in their true anatomic size and relationships, there are two basic principles that must be followed: 1) Endeavor to approach parallelism between the film plane and the plane of teeth regardless of the distance between the two. 2) Adopt the sixteen-inch anode-film distance to eliminate distortion produced by any increase in the object-film distance.

Five hundred twenty-four periapical radiographs of maxillary first and second molars taken with the bisecting technique were evaluated by three examiners. The number of times the zygomatic arch interfered with the reading of the six apices of maxillary first and second molars was recorded. An average of 20 percent of the apices of first molars and 24 percent of the apices of second molars were radiographically interfered with by the zygomatic arch. Authors concluded that for the endodontic radiographic diagnosis of maxillary molars, the bisecting angle technique has proven unreliable.[41]

The closer the object-film distance, the greater the degree of sharpness or definition of the image on film. Increasing the object-to-film distance decreases definition and results in blurring. The distance between the object and film are increased in the paralleling technique. Use of the conventional 8-inch anode-film distance is not sufficient to overcome the inherent loss of definition with increased object-film distance.[40]

An increase in anode-film distance requires an increase in exposure time. The time-distance law states that the time required for a given exposure is directly proportional to the square of the anode-film distance. Doubling anode-film distance from 8 inches to 16 inches requires an exposure time four times as great, which is impractical and increases patient exposure. This can be avoided by using a faster emulsion film.[40]

Angulation of the x-ray beam is another important consideration. Elongated, foreshortened, curved, or cone-cut images are produced when devices for positioning the films are not used.[39] Wengraf[42] in 1965 also evaluated angulation in periapical radiography. Two series of 99 and 100 patients, respectively, had two radiographs taken

each at different angulations. In the first series, they differed in a horizontal plane by 15° and in the second in a vertical plane by 15°. In horizontal angulation, where a rarefaction was present, it might be altered slightly in shape, but the size remained the same with insufficient variation for the diagnosis to differ. There were even fewer differences in apical appearance in the vertical series. The difference within each pair of radiographs was evaluated and found not to be marked. They concluded a radiographic standardizing device is probably not necessary for routine root canal therapy. Bender, Seltzer and Soltanoff[43] in 1966 expressed a different view. They stated that when postoperative films are taken at a different angle from the original film, the image can give the appearance of a smaller lesion, or that the lesion can be made to disappear completely. This is especially true if the follow-up film is foreshortened vertically, or if horizontal angulation is changed. The result can be mistakenly observed as successful. The reverse is also true if the lesion is small or not visible on the initial radiograph. A change in angulation can produce an image that is apparently larger, and the treatment may be erroneously recorded as a failure. Standardization in angulation or taking three films using three different tube positions can prevent errors in interpretation.[43] Walton[44] in 1973 stated that correct film placement and beam angulation are two very important factors in producing radiographs of accurate diagnostic resolution. Thunty[45] agreed in 1978 and stated misinterpretation of radiographs is due to faulty horizontal and vertical angulation that causes illusions in dental radiographs. An improperly directed beam results in overlap or superimposition of images.

To have consistent images of high radiographic quality, two basic objectives must be met. The first to produce clear images that are anatomically correct, and the second is

standardization using techniques that can be replicated to provide similar radiographs of diagnostic quality. The long cone paralleling technique was developed to meet these criteria. It produces the most error-free and anatomically accurate radiographs.[46] Evaluating the paralleling technique, Fitzgerald[38] in 1947 discovered an eight-inch cone gave little latitude in object-film distance. Magnification and unsharpness were evident when the film was placed further from the tooth. Using a 20-inch cone, x-rays are more nearly parallel, and the film can be placed further from the tooth, parallel to the long axis without considerable magnification or loss of detail.

An attempt to determine the best film position for maxillary dental radiographs was undertaken by Barr and Gron[47] in 1959. Maxillary casts were prepared from alginate impressions of 100 men and 50 women. Mean values were then computed for measurement of palatal height. Possible film positions were tested to determine the minimum object-film distance at which 3 mm or more of periapical view would be expected in greater than 8 percent of the cases. Direction of radiation in the vertical plane was reproduced according to a 16-inch anode-film distance, and the center of the beam was directed to the midpoint of the long axis of the tooth concerned. Results indicated true parallel film placement often resulted in inadequate visualization of the periapical area. Diverging film placement of less than 20° provided a more generous periapical view, no longitudinal distortion, but a less effective orientation of the depicted structures.

The visibility of interruptions of the integrity of lamina dura radiographically was evaluated at varying kilovoltages by Manson-Hing[48] in 1971. Mandibular premolars in a dry skull were removed, and dental burs were used to make openings or gaps in the

lamina dura of 0.040 in., 0.050 in., 0.075 in., and 0.100 in. Radiographs were taken with a 10 mA, 16-inch tube to patient distance, 2-mm aluminum total filtration, and Ultraspeed film. The range of kilovoltages was 50 to 90. Films were reviewed by 24 evaluators. Results indicated that for breaks in the lamina dura to be observed with a relatively high degree of accuracy, the gap must be 0.075 in. wide or more. Radiographic contrast produced with 60 kVp to 75 kVp appears to be most efficient.

Two clinical experiments by Thunty and Manson-Hing[49] in 1978 evaluated the effect of kVp and mAs on resolution and image-contrast percentage. Resolution was measured with a "test pattern" and image-contrast percentage was determined by a mathematical formula. Density of the film was kept constant in the first experiment by changing the kVp and mAs. In the second part of the experiment, different mAs were chosen, and for each mAs several kVps were used. The first experiment, with density remaining constant, revealed the higher the kVp, the lower the resolution and image-contrast percentage. The higher the mAs, the higher the resolution and image contrast percentage. The second experiment, when film density is not constant, the correlation among kVp, resolution, and image contrast remained the same. There was a negligible correlation between mAs, resolution, and image-contrast percentage. A high positive correlation was found between resolution and image-contrast percentage. A high negative correlation was found between resolution and film density.

CHARGE-COUPLED DEVICES

The charge-coupled device (CCD) was introduced by Boyle and Smith of Bell Systems Laboratories in 1970.[50] The use of CCDs in commercial products began in the

1970s and 80s. They are commonly found in a variety of electronic devices such as telescopes, microscopes and videocameras.

Charge-coupled devices allow the collection, organization, and display of light or x-ray photons by converting them to electrical charge. This is dependent upon the interaction of electromagnetic energy with the element silicon. Silicon atoms are bonded covalently to each other. Roughly 1.1 volt is required to break one bond, resulting in an electron-hole pair. Thousands of bonds can be broken by electromagnetic radiation.[51]

Miles reported the use of the CCD in radiographic imaging systems.[52] The CCD functions as the image receptor in a variety of imaging equipment. Charge coupling is the process of sequentially transferring the accumulated photons from one electron well to the next. Each well is commonly called a pixel (picture element). A charge pattern proportional to the number of electrons captured by each pixel is the result. This pattern is transferred to the output amplifier for conversion to a signal resulting in the digital image. In imaging science, resolution is quantified by how many line pairs per millimeter (lp/mm) that can be resolved. Current CCD technology allows resolution of 9-10 lp/mm. This can be compared with standard dental film, which has a resolving power of 16 lp/mm. Both systems are acceptable for unaided human vision, which has resolving capacity of 4-6 lp/mm.[52] The first use of the CCD in dentistry was its incorporation in the Sens-A Ray system for direct digital intraoral radiography.[53] It is also a component of other dental digital imaging systems such as: RadioVisioGraphy, Vixa/Visualix, Flashdent and Schick.

DIRECT DIGITAL IMAGING

Direct digital imaging (DDI) in dentistry utilizes two types of solid-state detectors that use CCD technology: a linear array detector for digital panoramic radiography, and an area array detector used for periapical and bitewing digital images. The latter utilizes a conventional x-ray source and an area array detector, which is used intraorally like a small cassette. The electronic image can be displayed on a videomonitor, converted to a digital image for storage, and printed on thermogenic paper. Some systems offer "enhancement" techniques in the real-time mode, such as a zoom feature, brightness control, and image reversal.[5] Advantages of DDI include lower absorbed x-ray dose, high signal-to-noise ratio, wide dynamic range, elimination of chemical processing, image reconstruction possibilities, computer storage capability, and images can be transmitted by telephone.[5] Disadvantages include higher initial cost, unknown life expectancy of the CCD, and many CCDs have a smaller size than film.[5]

Stored in its full resolution in computer memory, the digital intraoral radiograph occupies between 100 kB and 250 kB. The implementation of digital radiography in the dental office will require large electronic storage media and long transmission times.[54] Southard[55] in 1985 described a laser-based optical disc technique, which can store large numbers of digital radiographic images inexpensively. Digitized dental radiographs can also be archived. The practice of digital archiving of images has been recommended for optimal office organization.[56,57] The longevity of archivable quality is yet to be established but has been reported to be at least 10 years.[58,59]

A prototype system for archiving and transmitting digitized dental radiographs was discussed by Skov[60] in 1992. This technology would allow multiple users to access

images from different locations without physically transferring radiographs. Digitized radiographs can also be teletransmitted. Wenzel[61] in 1987 demonstrated that digitized radiographs with 64 shades of gray could be teletransmitted. The resulting image was diagnostically equivalent to the original radiograph.

Cannon and Hunt[62] explained an image expressed in digital form can be manipulated mathematically rather than optically. Utilizing this technology, they demonstrated a blurred photograph restored to clarity. The technique proved effective in dental radiographs as well. Deficiencies such as low resolution and lack of contrast were alleviated.

The possibility of exporting digital images, altering them, and restoring them to the drive without any visible signs of alteration was explored by Bruder et al.[63] in 1999. Images stored on the hard drive of a Schick computer dental radiography system were downloaded. They were opened in Corel Photo Paint, where images were altered, and manufacturer export signals, edited. Digital images were relatively easy to export and alter with the use of a photo-editing program. Authors stressed the need to implement technologies to safeguard digital radiography, to prevent potential abuses.

Digital imaging is now widely used in the medical field and has provided the ability to produce images displaying a physiologic process or the function of an organ. Traditional images are based solely on anatomic detail. Radiologists can now assess velocity and patterns of blood flow, organ and tissue perfusion, and patency of vascular grafts.[64] Ram[65] in 1982 demonstrated several images deemed unsatisfactory for medical analysis. Following various image enhancement techniques with digital radiography,

they achieved diagnostic quality. This advancement can help avoid repetitive administration of radionucleotides and ionizing radiation exposures.

Comparing DDI with conventional radiography for detection of proximal surface caries, Computed Dental Radiography (CDR) by Schick Technologies Inc., (Long Island, NY) was compared with E-speed film. Three hundred and twenty extracted teeth were imaged and viewed by 16 dentists. Dentists using the DDI performed as well in interpreting proximal surface caries as with E-speed film.[66]

DDI was also compared with conventional radiography for detection of periapical bone lesions. Block sections from six dry human mandibles were taken from the canine region distally to the molars. Sections were split into buccal and lingual halves. Periapical lesions of 1 mm, 3 mm and 5 mm were created with burs. Twenty images of roots with lesions of different sizes and 16 images of roots without a lesion were created using the Visualix/VCA system and conventional radiography with E-speed film. Seven observers rated the presence or absence of a lesion using a five-point scale. No statistically significant difference in diagnostic accuracy was seen between the two techniques.[2]

DIGITAL IMAGING SYSTEMS

Incorporating CCD technology into direct digital imaging for use in dentistry has been accomplished by a few corporate competitors. Radiovisiography (Trophy Radiology, Marietta, GA) introduced in 1989, was the first system ready for clinical use. The RadioVisioGraphy (RVG) sensor is a scintillation screen/fiber-optically-coupled design.[67] X-rays cause phosphorescence of the screen in the visible light spectrum. The light photons are then transferred by prismatic optical fibers to the surfaces of the CCD.

Mouyen and associates[68] in 1989 identified two major disadvantages of conventional film as a "fairly high" radiation dose and interruption of treatment during film processing. They noted RVG has the ability to produce an almost instantaneous image following exposure and at a lower dose.

RVG required only 22.3 percent of the radiation exposure used in the conventional technique to obtain clinically acceptable images. Problems noted were a lack of sensor flexibility and the limited size of the surface sensitive to x-rays. Authors concluded the system effectively complements conventional film radiography.[69]

Sixty extracted teeth, including 94 root canals, were imaged using RVG and conventional radiography with E-speed film. Two investigators evaluated each image for the presence or absence of a root canal. There was no statistically significant difference between the percentage of length of a root canal visible on conventional film and that visible on RVG images. Radiovisiography has the advantage of being a rapid, low-dose imaging technique.[70]

Leddy et al. in 1994 compared RVG with E-speed film for determination of working length. Human cadaver sections with first or second molars were used. Forty-five maxillary molar canals and thirty mandibular molar canals had files inserted randomly from 4 mm short of the radiographic apex to 3 mm beyond. Conventional radiographs and RVG images were evaluated by three endodontists to determine the adjustment needed to place the file 0.5 mm from the radiographic apex. It was found that accurate file length adjustments can be made from an image two times larger than the actual tooth. RVG was not significantly better than conventional radiography.

Investigators concluded if both methods are available, RVG is preferred, because of the significant reduction (80 percent less) in radiation dose.[71]

Yokota and associates[72] compared RVG with conventional radiography for diagnostic potential in detecting periapical lesions. Lesions were created in human cadaver specimens by extracting teeth and removing periapical bone with a slow-speed handpiece and round burs. Teeth were replaced and radiographed conventionally and with RVG. Images were evaluated by three endodontists. Results were: a) when no lesion existed, conventional radiographs were more diagnostic than RVG; b) when lesions were enlarged to involve lamina dura and medullary bone, RVG was superior; and c) no difference was found between conventional radiography and RVG when the lesion involved cortical bone.

The Sens-A-Ray system (Regan Medical Systems AB, Sundsvall, Sweden) as discussed by Welander[67] in 1992 was the first with a CCD detector designed for direct conversion of x-ray energy to electronic signal. It provided images of adequate diagnostic quality at one-half to one-third the exposure required by E-speed film.[73]

Diagnostic accuracy of D-speed and E-speed film in the detection of simulated periodontal bone lesions was compared with Sens-A-Ray direct digital image receptor. Lesions of increasing depth (1.0 mm to 3.0 mm) were created in interproximal marginal bone with 1.4-mm diameter round burs in 11 human mandibles. Specimens were images at each lesion stage with the use of all three receptors. Nine viewers used a 5-point rating scale to evaluate whether the lesions were present or absent in the resulting images. No statistical difference was found between any of the three image receptors for detection of

simulated periodontal lesions 1.0 mm to 3.0 mm in depth. This would suggest that the digital system performed comparably with conventional film systems.[74]

McDonnell and Price[75] compared resolution of D- and E-speed film with the Sens-A-Ray system. Line pair images used in the evaluation were not as clear with the Sens-A-Ray, but it could resolve 10 line pairs per mm, which is beyond the resolving power of unaided human vision.

Visualix (VIXA in North America) is a commercial system for direct dental x-ray imaging. It is based on a CCD sensor and a personal computer platform. Application software is installed and provides a user interface for real-time imaging. At full-scale range the dose requirements are six times less than those for a D-speed film.[76]

Scarfe, Farman and Kelly[77] evaluated the Flash Dent system by Fiad (Villa Sistemi Medicali, Buccinasca, Italy). The system utilizes an area array CCD with an intensifying screen. This sensor differs from that of the RVG system in that light is transmitted to the detector by a set of lenses rather than a fiber optic bundle.[78] They found the image receptor handle bulky and difficult to position. Inconsistencies between sensors and the use of a non-standardized image format were also noted.

The Computed Dental Radiography (CDR) CCD sensor (Schick Technologies, Inc.) was utilized in the first version of Schick's DDI system.[4] It is claimed by the manufacturer to resolve 10 line pairs per mm. A CDR proprietary image processing algorithm increases image contrast on the display.[66] A new development in the sensor component is the complementary metal-oxide semiconductor active pixel sensor (CMOS-APS). It has an active transistor built into each pixel and provides a reduction by a factor of 100 of the system power required to process the image compared with the CCD. The

APS system eliminates the need for charge transfer and may increase the reliability and lifetime of the sensor.[4]

COMPRESSION OF DATA

Despite advances in low-cost, high-capacity storage technology, image compression is essential for modern diagnostic radiology, because digital images require large amounts of storage. Image compression is the process of converting an image into a file that is significantly smaller than the original. The small size of a compressed file is an advantage, because more images may be stored on a given device. Compression also benefits image transmission. An image transmitted in compressed form over the computer network can be transmitted in a shorter period, and more images can be sent.

Gillespy and Rowberg discussed the two methods of data compression for storage purposes:

> Compression methods are generally classified as lossless (or reversible, nondestructive, bit-preserving) or lossy (or nonreversible, destructive). Lossless compression algorithms can restore a compressed image to an exact digital replica of the original, whereas lossy compression algorithms always change the image in some manner compared with the original. Lossless image compression commonly achieves compression ratios of 1.5:1 to 3:1 (33% to 67%), whereas lossy compression can compress images from 3:1 to 30:1 (67% to 97%).[79]

They also explained that image compression is possible due to redundant information found in most images. This requires more bits than necessary to store the image, and it is compressed by simply removing the redundancy.

Bramble[80] in 1989 utilized lossless compression combining differential and Huffman encoding for computed tomographic images of 512 kB. Compressed images were then compared with the original uncompressed images for storage on a 192-Mbyte

hard disc and transmission time over telephone at 4,800 bits per second. Five hundred uncompressed images could be stored on a hard disc, and transmission time was 20 minutes. At compression of 3.4:1, 1,340 images were stored on hard drive, and telephone transmission time was six minutes. At a compression ratio of 2.3:1, 1,100 images were stored on hard drive, and transmission time was six minutes.

High-resolution digital mammograms contain 10 to 40 Mbyte each. Storage and transmission becomes a problem when dealing with a large number of these images. Image compression techniques have the potential to greatly reduce this problem. Joint Photographic Experts Group (JPEG) compression at five different levels ranging from 15:1 to 60:1 was accomplished for eight high-resolution mammograms by Good, Maitz and Gur[81] in 1994. At a compression of 15:1 image-processing experts were unable to detect any difference from the original image. At levels of 60:1 they were able to detect the difference 100 percent of the time. This study was accomplished as a first step in optimizing compression for reader performance studies.

Effectiveness of lossless compression of 3,679 grayscale medical images was evaluated by Clunie[82] in 2000. Traditional JPEG was compared with the new JPEG-LS (ISO/IEC 14495-1) and JPEG 2000 scheme (ISO/IEC CD 15444-1). JPEG-LS and JPEG-2000 performed equally well and both outperformed traditional JPEG. JPEG-LS is faster, simple, easy to implement, and consumes less memory than JPEG 2000. JPEG 2000 has the advantage of offering lossy compression and progressive transmission.

"Image compression is considered lossy if the compressed image file is not numerically identical to the original file after it has been restored."[83] The advantage of lossy image compression is that it is capable of much higher compression ratios than

lossless compression. Disadvantages include loss of diagnostically useful information, and image-compression artifacts may be visible. There is no consensus on the acceptable level of lossy image compression. When quantitative measurements are desired, the technique is undesirable, because original pixel values are altered.

Lossy compression is accomplished in three stages: transform coding, quantization, and compression. The transformation stage is usually lossless and converts the image into a format that is more suitable for compression. The discrete cosine transformation and discrete wavelet transformation are two commonly used methods. The quantization stage is the lossy step in the process, and it reduces the number of different output values in the transformation stage. The final compression stage compresses the quantized coefficients.[83]

The JPEG standard is the technique agreed upon to archive and to transport images in medical fields. The technique is based upon lossy compression of images. It can handle x-ray and full color images and is suitable for introduction into picture archiving and communicating systems (PACS). Images can be handled after compression as small clusters of data. An important factor in the design of this technique is that this format requires no specific hardware or software if using JFIF (JPEG File Interchange Format). Soon this algorithm will be able to run on any personal computer in the world. Highly compressed images may be unsuitable for diagnostic purposes but may be sufficient for reference images.[7]

Bramble[80] accomplished lossy compression by suppression of data outside of the body or head and the combination of differential and Huffman encoding for computed tomographic images. Storage and telephone transmission times were compared with

uncompressed images. At 512 kB per image, 500 images could be stored on a 192 Mbyte hard disc, and telephone transmission at 4,800 bits per second required 20 minutes per image. At a lossy compression of 5.1:1, 2,010 images were stored on a hard disc and telephone transmission required four minutes per image. At 4.7:1 ratio, 1,850 images were stored on hard disc, and telephone transmission required four minutes. More images were stored and could be transmitted by telephone more quickly following compression.

Irreversible image compression was accomplished for chest images with computed radiography using the modified bit-allocation technique (adaptive quantization DCT).[84] One original and five reconstructed images with compression ratios of 3:1, 6:1, 13:1, 19:1 and 31:1 were ranked according to quality. Images were assessed by six radiologists, and the acceptable upper limit of the compression ratio was 19:1. To assess the ability to detect the presence or absence of nodules and linear shadows, 30 plain chest, computed-radiography images were compressed with ratios of 5:1, 10:1, 20:1 and 25:1. Six radiologists rated the presence or absence of a lesion using a five-point scale. A compression ratio of 10:1 was found to be acceptable, and 20:1 was the upper limit for acceptable compression ratios on chest computed-radiography images. A compression ratio of 25:1 showed a statistical difference when compared with ratios of 20:1 or less.

To determine the effect of data compression on diagnostic accuracy, observer tests were performed with 60 digitized chest radiographs containing examples of pneumothorax, interstitial infiltrate, nodules, and bone lesions.[85] Radiographs with no compression, and with compression ratios of 25:1 and 50:1 were presented in random

order to 12 radiologists. It was determined that ratios as high as 25:1 may be acceptable for primary diagnosis in chest radiology.

The effect of lossy image compression on diagnostic accuracy in thoracic computed tomographic (CT) images was evaluated.[86] Sixty images from patients with mediastinal adenopathy and pulmonary nodules were chosen. Images were compressed with tree-structured vector quantization to ratios of 21:1, 10:1, 9:1, 7:1, 5.5:1, and 4.5:1. Three radiologists used original and compressed images for diagnosis. Diagnostic accuracy was maintained to compression ratios of 9:1 for pulmonary nodules and mediastinal lymph nodes on thoracic CT images.

One hundred sixteen extracted human molars and premolars were radiographed with the Digora system (Sorodex Medical Systems, Helsinki, Finland).[54] Images were compressed with the Lempel-Ziv-Welch reversible methods and the Joint Photographic Experts Group's irreversible compression on four levels. Five observers viewed a total of 580 images. Observers ranked each image on a five-rank confidence scale for the presence of caries and subjectively judged image quality using an 11-point scale. Authors determined compression rates of 1:12 can be justified before accuracy and image quality are significantly affected. The median quality score was above middle on the 11-point scale, except for the most compressed images.

RADIOGRAPHIC INTERPRETATION

Reproducibility of radiographic interpretation by an examiner (intra-examiner agreement) or examiners (inter-examiner agreement) has been extensively studied. Garland[87] in 1950 studied examiner agreement utilizing radiographic surveys for tuberculosis. He cited a 1944 study of chest films showing intra-examiner agreement

ranging from 76 percent to 95 percent. Inter-examiner agreement varied from 69 percent to 97 percent. He listed competence of the examiners, the use of dual readings, and the quality of the radiograph as factors influencing reliability.

Brynolf[88] utilized a series of radiographs of upper incisors to test reproducibility of the interpretation of the radiographic appearance of the periapical area by the same examiner on different occasions. Two groups of radiographs were used. One contained a single view, and the other contained three views at differing angles. Evaluators were asked to record various anatomic details of periapical structures and diagnose the condition as normal or as in one of five groups representing pathologic changes. On division into the six diagnostic groups, the interpretation was reproduced in 70 percent of cases when one radiograph was used, and 87 percent when three radiographs were used.

Three hundred thirty cases were selected by Zakariasen[89] in 1974 from an endodontic practice. Post-operative and recall radiographs were examined by four endodontists for an interpretation of treatment success or failure. One hundred eighteen cases were examined a second time by each endodontist. Data for four examiners showed 64.5-percent intra-observer agreement, 74.4-percent intra-observer agreement, 79.3-percent intra-observer agreement, and 81.0-percent intra-observer agreement.

The same 253 cases that had been examined by six independent examiners previously were reexamined eight months later by three of the original examiners.[90] Each examiner's results were then compared with his original results. They agreed with themselves anywhere from 72 percent to 88 percent of the time in various categories. The analysis, however, showed large discrepancies in almost all categories of comparisons. Haugejordan and Slack,[91] using one dental examiner, found even greater

discrepancy. For caries diagnosis over a 22-month period, intra-examiner agreement was only 20 percent.

A board of roentgenology, composed of three chest specialists and two radiologists, was established in 1944 to investigate the relative diagnostic efficiency of various radiographic techniques.[92] Independent interpretations of four sets of films were made by each of the five members. They discovered that their interpretations differed from their colleagues, and they also disagreed with themselves a significant percentage of times. They concluded that anytime human senses were involved in making a judgment, there was inter- and intra-evaluator variation. The board recommended a detailed study of the problem.

Ten experienced dentists traced 45 periapical radiolucencies.[93] Comparing first and second interpretations revealed an average relative error of interpretation of 21 percent for area measurements of well-defined radiolucencies, and 37 percent for diffuse radiolucencies. A comparison between the 10 dentists revealed the relative error of interpretation by means of measurements varied from 14 percent to 32 percent for well-defined radiolucencies, and from 23 percent to 52 percent for the diffuse radiolucencies. Differences in interpretation were more obvious in the area measurements than in determining the largest diameter or in the largest distance between the root surface and the outline of the radiolucency.

Endodontic success and failure of 253 cases selected at random were determined by mounting the films and having six examiners read them.[94] All examiners read the films independently and without counseling one another. They agreed on less than half the cases. When the question was only one of determining whether an area of rarefaction

was or was not present on one film, the agreement was still less than half. Upper molars gave the greatest percentage of disagreement, but all the other teeth gave large percentages of disagreement also.

In 330 cases selected from an endodontic practice, success or failure was interpreted radiographically.[89] Postoperative and recall radiographs of each case were examined by four endodontists for an interpretation of treatment success or failure. With four examiners and three diagnostic categories, they found approximately 38-percent agreement.

Three endodontists and three radiologists interpreted periapical conditions and quality of root fillings in radiographs of 119 endodontically treated roots.[95] Agreement of 27 percent was found for the presence of a periapical lesion. A 6-percent agreement was noted for determining increased width of the periodontal ligament. Normal periodontal conditions had 37-percent agreement; adequate fill had 25-percent agreement, and defective fill had 12-percent agreement. Examiners concluded that, " the large variation noted among clinical and radiographic studies on the results of endodontic therapy could partly be explained by difficulties in defining and maintaining criteria for radiologic evidence of periapical disease."

Ten dentists evaluated 56 radiographs, and the influence of 18 radiographic features on the consistency and reliability of interpretation of the periapical area was investigated.[96] Results indicated that the pattern, size, and density of bone trabeculae are the best radiographic features for identifying healthy teeth. The most consistent radiographic features aiding diagnosis of the periapical condition of teeth were the continuity and shape of the lamina dura, and the width and shape of the periodontal

ligament space. Changes in these features were observed by all observers but were not always considered in the final assessment interpretation. Authors determined the importance of interpretation of these features should be emphasized to improve correct radiographic diagnosis and decrease inter-observer variations.[96]

Dental students and dental radiologists evaluated the presence or absence of caries on previously extracted teeth.[97] When given information prior to evaluation, such as percentage of lesions actually present, it changed observer performance significantly. Examiners told that 75 percent of surfaces were carious registered a greater number of lesions than those told that 25 percent of surfaces were carious.

Eckerbom, Anderson and Magnusson[98] in 1986 evaluated inter-observer agreement. They stressed the importance of extensive calibration to increase viewer agreement. They discovered a decrease in error rate if the examiners were trained together.

Valachovic and associates[99] attempted procedures to improve inter-examiner and intra-examiner agreement in radiographic diagnosis of caries and periodontal disease. Four examiners reviewed 150 films at three-month intervals for 24 months. Standardization sessions were held prior to each session to ensure that diagnostic criteria were clear, and that discrepancies in individual interpretation of the criteria were identified and corrected. Following these procedures both intra-examiner and inter-examiner agreement remained high throughout the length of the study. Using the kappa statistic, levels remained high, 0.7 to well over 0.8, for both caries and periodontal disease.

The effect of training level on the accuracy of chest film interpretation was evaluated by Herman and Hessel.[100] When comparing first-, second- and third-year radiology residents and practicing radiologists, no statistically significant difference was found in diagnostic accuracy. Actually, a first-year resident was found to have the fewest errors. Investigators concluded, "Individual abilities, perceptual and otherwise, may have a stronger influence on accuracy than the length of formal training." Conversely Patel and associates[101] found qualified dental staff had significantly higher specificities than fourth- and fifth-year students when a viewing box alone was used in diagnosing early periapical inflammatory pathosis of 18 periapical radiographs.

Antrim[102] compared three viewing techniques to see if one was superior to the others in the evaluation of radiographic evidence of periapical pathosis. Six evaluators viewed 260 radiographs three times. The viewing techniques were: view box illumination; use of a Productor magnifier viewer that enlarges the radiograph four times and eliminates extraneous light; and projection of mounted radiographs on a screen with a 35-mm carrousel projector (Eastman Kodak Co.). Evaluators waited one week between viewings to minimize familiarization. Agreement on the presence, absence, or uncertainty of periapical pathosis utilizing the viewbox was 52.3 percent. The magnifier viewer had 48.1 percent agreement and projected radiographs had 44.2 percent agreement. Authors concluded that the radiograph is a very questionable means of determining endodontic success, because it is based on a subjective analysis of an observable area of pathosis. Different viewing techniques do not seem to improve diagnostic reliability.

Welander and associates studied the effect of different viewing conditions on the perception of radiographic detail by using a test object.[103] A rectangular piece of aluminum 7 mm thick was drilled to produce 10 cylindrical holes 2 mm in diameter and depths that varied from 0.05 mm to 0.50 mm. The test object was radiographed at 70 kVp and 15 mA with successively increasing exposure times. The radiographs of varying density were evaluated by four groups of 10 people. The first group viewed the radiographs under normal room lighting with a viewbox and no masking. The second group viewed the films under normal room lighting by holding them up to a ceiling light. The third group viewed the films under dim room lighting with a viewbox and masking to block extraneous light. The fourth group used normal room lighting with a viewer (X-Produkter, Sweden) to block out extraneous light. Perceptibility curves revealed groups one and two to be nearly identical. Groups three and four had no significant difference but had a much greater area within the curve, and the level was higher. Results indicate a greater amount of object detail is visible when optimum conditions are used. Extraneous light reduces the perceived image contrast and reduces the maximum density where contrast can still be perceived. Suggestions included blocking extraneous light from the viewbox, and that room light should be dimmed to keep reflected light at a minimum.

Patel et al.[101] in 2000 evaluated the effect of viewing conditions upon diagnosis of early periapical inflammatory pathosis on intraoral radiographs. Using three differing viewing conditions, it was concluded that use of a viewing box was superior to room lighting. Optimal sensitivity (78 percent) and specificity (78 percent) were obtained with masking and X2 magnification.

Brynolf[104] in 1970 attempted to discern the number of radiographs required for rendering a diagnosis of periapical pathosis. Results were then compared to the true histologic diagnosis of 212 maxillary incisors extracted immediately after the radiographs. The author concluded satisfactory diagnostic reliability with a single radiograph. Where a more refined diagnosis is required, three or more radiographs taken in different projections should be obtained of the area in question.

Brynolf[105] also evaluated radiographic interpretation with varying radiographic techniques. Again 212 upper incisors were radiographed, and results were compared with the correct histological diagnosis. Results revealed radiographs taken with a tubular diaphragm were valuable for diagnosis in "normal" cases but might complicate diagnosis of pathologic cases. The eccentric view was of diagnostic value in pathologic cases but complicated diagnosis in normal cases, because an oblique view of normal structures can simulate the appearance of pathosis.

Examiners can also be influenced by motivation as witnessed by Goldstein and associates.[106] Dental students were asked to identify the presence or absence of periodontal disease, caries, and apical pathosis in dental radiographs. Cash bonuses of $3.00 per diagnosis were offered to one group for correct identification of pathosis. The other group of dental students was offered no cash incentive. The number of false positives in the incentive group was significantly higher.

Goldman et al.[94] utilized six examiners for radiographic interpretation of endodontic success. The examiner who reported the least amount of endodontic failures was the one who had treated most of the cases. The mental state of the examiner at the time of interpretation was also cited as an influence. Factors such as fatigue, emotional

state, and the involvement of the examiner were all significant factors. In another study Valachovic and associates[99] limited interpretation sessions from 90 minutes to 120 minutes to minimize bias from fatigue.

Zakariasen et al.[89] selected 330 cases from an endodontic practice. Post-operative and recall radiographs of each case were examined by four endodontists for an interpretation of treatment success or failure. The cases were then categorized by average radiographic density differences within radiographic sets, anatomic location of treated tooth, technical compatibility within radiographic sets, and by length of time between postoperative and recall radiographs. These factors did not affect reliability of success-failure interpretation.

Jensen[107] explored the importance of image perception in radiographic interpretation. A standard x-ray test pattern (Type 39, Nr. 2, 2918, Nuclear Associates, Inc., New York) was viewed by seven evaluators in a dimly lit room with a view box and masking at a distance of 25 cm. Average image perception in "naked eye" viewing was 9.01 line pairs per millimeter (lp/mm) and with a magnifying glass average perception improved 77 percent to 15.9 lp/mm. The study also showed human visual acuity may allow perception of resolutions up to 20 lp/mm. Use of a magnifying glass could expand visual perception of image details as much as 135 percent.

Radiographic interpretation of endodontic lesions was summarized by Tidmarsh.[108]

The radiographic interpretation of pathological lesions which are endodontic in origin is relatively imprecise as so many variables are involved. Even the presence or absence of a lesion cannot be determined with accuracy and there is little agreement on the criteria which should be applied. Strict attention to the technique of exposing, processing and viewing radiographs is necessary if the information to be gained is to be optimal. The major problem of visual interpretation and the psychological factors

involved have been subjected to a certain amount of study and recent work on the mental processes of the clinical decision making provide further insight. There is considerable promise being shown by methods of computer analysis and image enhancement and it may be that further development in these fields will provide the degree of objectivity that is essential if improved accuracy in diagnosis is to be achieved.

DIRECT DIGITAL IMAGING FOR DETECTION OF PERIAPICAL PATHOSIS

A comparison among Ektaspeed Plus film, a CCD sensor (Schick Technologies, Inc.) and a complementary metal-oxide semiconductor active pixel sensor (CMOS-APS) for detection of periapical bone lesions was accomplished by Paurazas and associates 2000.[4] Lesions were created with round burs in cortical and trabecular bone of human mandibles with round burs and imaged with the three techniques. Diagnostic accuracy was not significantly different for seven evaluators when using film and direct digital imaging techniques.

Tirrell et al.[3] compared conventional radiography and DDI with RadioVisioGraphy in detecting chemically created lesions in bone. A 70-percent perchloric acid solution was used to create lesions on the buccal cortical plate of human cadaver jaw specimens. Images were viewed twice by five evaluators. There was no difference between the two techniques in early detection. At 12 hours and 24 hours after application, direct digital imaging demonstrated more lesions than conventional radiography. At 36 hours, 48 hours, 72 hours, and 96 hours, there was no significant difference between the two techniques.

Detection of periapical bone lesions in 50 patients was compared by Kullendorff and associates[109] using conventional radiography with Ektaspeed film and direct digital imaging using the Visualix/VIXA system. Seven observers assessed 59 roots using a

five- point confidence scale. It was concluded that conventional film radiography performed slightly better than direct digital imaging for detection of periapical bone lesions. Image processing did not improve the observer performance.

Barbat and Messer[1] compared conventional radiography with direct digital imaging using the Digora system for detection of artificially created periapical lesions in human cadavers. Lesions were created with burs and varied in size from the removal of lamina dura only, extension to cancellous bone, and involvement of the cortical plate. Eight observers scored lesions on a five-point confidence scale. Lesions were detectable with both image systems with the removal of the lamina dura only and were increasingly detectable with further bone removal. No statistically significant difference was found between the two techniques. The use of color and reverse imaging resulted in a greater spread of diagnostic scores.

MATERIALS AND METHODS

CASE SELECTION

One hundred clinical periapical dental images were selected from the DDI database, (Schick Technologies Inc., Long Island City, NY) located in the Endodontic Graduate Clinic at Indiana University School of Dentistry. Images were exported from DDI software as a targeted image file format (TIFF). TIFF images were converted to JPEG images for evaluation. A single root was selected in each image and these roots were identified by a digital marker (Figure 1). A gold standard was set by two panelists (an endodontist and second year-endodontic resident that were not used as evaluators in the study). Classification of 100 images (four groups of 25 images) based on periapical lesion presence and diameter (Figure 2) was completed. One panelist reviewed the database alphabetically until 200 images (50 in each of the four groups) were selected. The second panelist reviewed the selected images from each group. The first 25 images in each group where panelist agreement was reached were used in the study. Periapical areas of roots identified in each image were classified as:

Group 1- (25 images) No periapical radiolucency (Figure 3).
Group 2- (25 images) Periapical radiolucency 0.1 mm to 2.0 mm in diameter (Figure 4).
Group 3- (25 images) Periapical radiolucency 2.1 mm to 3.9 mm in diameter (Figure 5).
Group 4- (25 images) periapical radiolucency 4.0 mm or greater in diameter (Figure 6).

COMPRESSION

All 100 images were subjected to the following compression ratios: 1:1, 1:8, 1:20, 1:40, 1:60, 1:80, giving a total of 600 images. The JPEG 2000 image coding system (Health Imaging Research Laboratory, Eastman Kodak Company, Rochester, NY) was utilized for the compression of images. Images were viewed under dark room conditions on a 17-inch cathode ray tube monitor, COMPAQ QVISION 210 (Figure 7).

IMAGE INTERPRETATION FOR PRESENCE OF A LESION

All images (600) were randomized utilizing IUSD Image software and viewed three times by three second-year endodontic residents. Viewing sessions were limited to two hours to limit fatigue and were scheduled a minimum of seven days apart to minimize recall bias. Evaluators were asked to evaluate the periapical area identified in each image and classify their interpretations according to a lesion presence rating scale:

1 = Definitely present.
2 = Probably present.
3 = Uncertain.
4 = Probably not present.
5 = Definitely not present.

Evaluators were standardized in interpreting each classification of periapical lesion by reviewing sample images of each classification of periapical lesion with a gold standard panelist. Written instructions were provided and reviewed prior to each viewing session.

EVALUATION OF IMAGE QUALITY

The three evaluators also evaluated the visual quality of each image. Perceived quality was recorded utilizing an image quality rating scale as:

1 = Excellent quality.
2 = Above average quality.
3 = Average quality.
4 = Below average quality.
5 = Poor quality.

Evaluators were standardized with oral and written instructions and were given examples of images in each of the five categories. Quality of the entire image was to be considered and not the periapical area only.

EXAMINER AGREEMENT

Inter and intra-examiner agreement for the presence of a lesion and image quality were assessed using intraclass correlation coefficients (ICC). The ICC were calculated for each of the six compression ratios. Calculations were also accomplished for each of the four lesion sizes within each compression.

To determine if compression had an effect on determining the presence of a lesion and image quality, a generalized linear mixed model was fit to each of these variables. Compression, lesion size, and the interaction between compression and size were fixed effects in the model. The random effects were the examiner and the image. Comparisons were made between different compression ratios and lesion sizes. The Sidak multiple comparison adjustment method was used to control the overall confidence level at 95 percent. A statistically significant difference exists if the p-value is less than 0.05.

RESULTS

Average intra-examiner agreement for the detection of the presence of a lesion had an ICC of 0.81. The ICC of each examiner for the detection of the presence of a lesion ranged in value from 0.76 to 0.89 (Table I). The ICC for intra-examiner agreement of presence of a lesion for each compression ranged from 0.74 to 0.91 (Table II). The inter-examiner agreement for presence of a lesion had an ICC of 0.72. The inter-examiner agreement for presence of a lesion for each compression ranged in ICC value from 0.70 to 0.75 (Table III). Presence of a lesion was significantly affected by lesion size ($p < 0.0001$). The effects of compression ($p = 0.9694$) and the interaction between size and compression ($p = 0.9977$) were not significant. Overall, there were no significant differences in the presence of a lesion score between compressions. The effect of lesion size on detection of lesion presence is shown in Table IV.

Average intra-examiner agreement for image quality had an ICC of 0.31. The ICC for each examiner for overall perception of image quality ranged in value from 0.07 to 0.58 (Table V). The ICC for intra-examiner agreement for perception of image quality at each level of compression ranged in value from 0.04 to 0.64 (Table VI). The inter-examiner agreement for image quality had an ICC of 0.19. The ICC for inter-examiner agreement for image quality at each compression level ranged in value from 0.11 to 0.23 (Table VII).

Compression ($p < 0.0001$) and lesion size ($p = 0.0325$) were significant effects on perceived image quality, but the interaction between these effects was not ($p < 0.9294$). Overall, there was a significant difference between compressions 1 and 40 ($p \leq 0.0001$),

60 ($p \leq 0.0001$) and 80 ($p \leq 0.0001$). There was no significant difference between compressions 1 and 8 ($p = 0.9454$) or compression 1 and 20 ($p = 0.2250$). There was a significant difference between compression 8 and 40 ($p < 0.0001$), 60 ($p < 0.0001$) and 80 ($p < 0.0001$). There was also a significant difference between compressions 20 and 40 ($p = 0.0010$), 60 ($p < 0.0001$) and 80 ($p < 0.0001$). Compression 40 was significantly different than 60 ($p = 0.0107$) and 80 ($p < 0.0001$). However, there was no significant difference between compression 60 and 80 ($p = 0.0776$).

When there was no lesion present, there was a significant difference between compressions 1 and 40 ($p = 0.0339$), 60 ($p < 0.0001$) and 80 ($p < 0.0001$). There was a significant difference between compressions 8 and 60 ($p < 0.0001$), compressions 8 and 80 ($p < 0.0050$) and compressions 20 and 80 ($p < 0.0001$). There were no significant differences between compressions 40 and 60 ($p = 0.9994$) or compressions 40 and 80 ($p = 0.2506$).

When the lesion size was 0.1 mm to 2.0 mm, there was a significant difference between compressions 1 and 60 ($p = 0.0023$) and compressions 1 and 80 ($p < 0.0001$). There was also a significant difference between compressions 40 and 80 ($p = 0.2506$).

When the lesion size was 2.1 mm to 4.0 mm there was a significant difference between compressions 1 and 60 ($p = 0.0033$) and compressions 1 and 80 ($p < 0.0001$). There was also a significant difference between compressions 8 and 80 ($p = 0.0250$) and compressions 20 and 80 ($p = 0.0046$).

When the lesion size was > 4.0 mm, there was a significant difference between compressions 1 and 60 ($p = 0.0012$) and compressions 1 and 80 ($p < 0.0001$). There was also a significant difference between compressions 8 and 60 ($0 = 0.0291$) and

compressions 8 and 80 ($p < 0.0001$). Compression 20 and 80 ($p = 0.0011$) also had a significant difference.

TABLES AND FIGURES

TABLE I

Overall intra-examiner agreement in determining presence of a lesion[a]

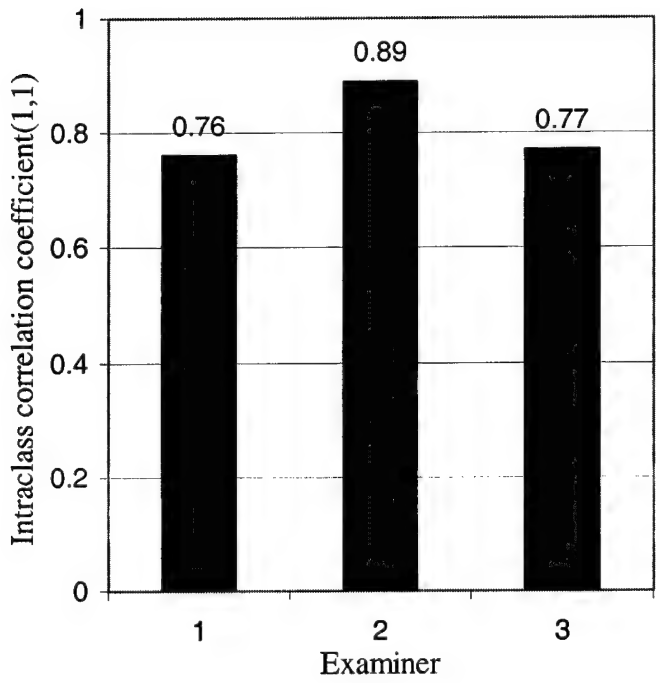

[a] An ICC of 1 would represent complete agreement by the examiner for all three viewings.

TABLE II

Intra-examiner agreement of presence of a lesion for each level of compression [a]

Compression	Examiner	ICC (1,1)
1:1	1	0.74
1:1	2	0.89
1:1	3	0.82
1:8	1	0.75
1:8	2	0.87
1:8	3	0.79
1:20	1	0.76
1:20	2	0.87
1:20	3	0.75
1:40	1	0.74
1:40	2	0.89
1:40	3	0.75
1:60	1	0.76
1:60	2	0.89
1:60	3	0.75
1:80	1	0.82
1:80	2	0.91
1:80	3	0.77

[a] An intraclass correlation coefficient (ICC) of 1 would represent complete agreement by an examiner for all viewing sessions within the corresponding compression ratio. Compression ratio did not have a significant effect on the detection of the presence of a lesion.

TABLE III

Inter-examiner agreement in determining presence of a lesion at each level of compression[a]

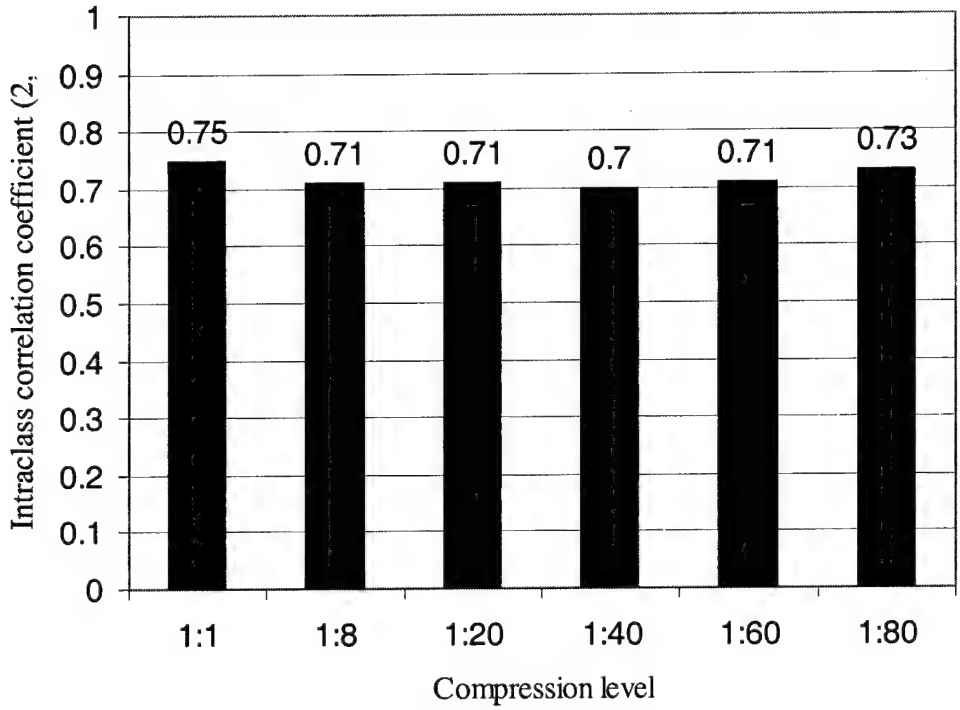

[a] An ICC of 1 would represent complete agreement among the three examiners within the given compression ratio. Compression did not have a significant effect on the detection of the presence of lesion.

TABLE IV

Examiner response in determining presence of a lesion expressed as a percentage using the lesion presence scale[a]

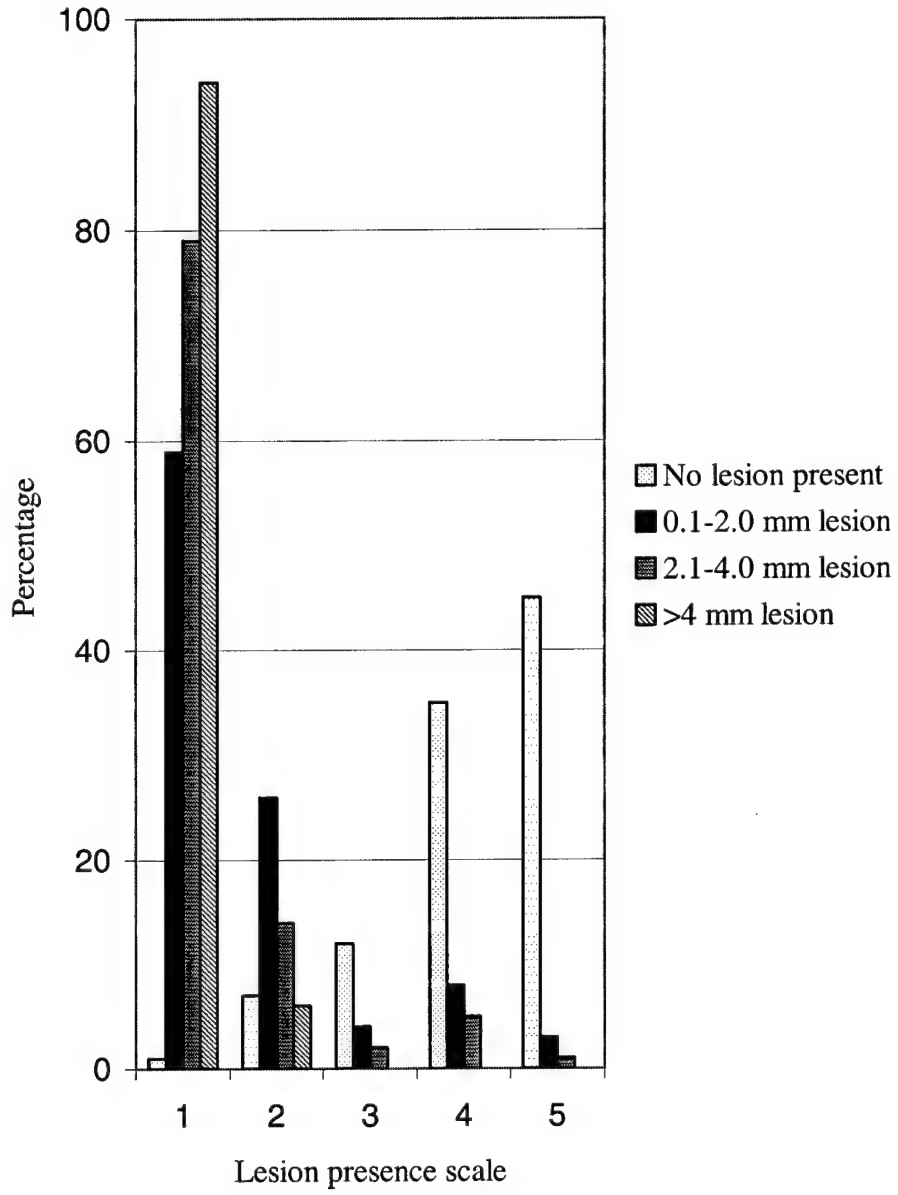

[a] Lesion presence scale: 1 = Lesion definitely present; 2 = Lesion probably present; 3 = Uncertain; 4= Lesion probably not present; 5 = Lesion definitely not present.

TABLE V

Overall intra-examiner agreement in determining image quality[a]

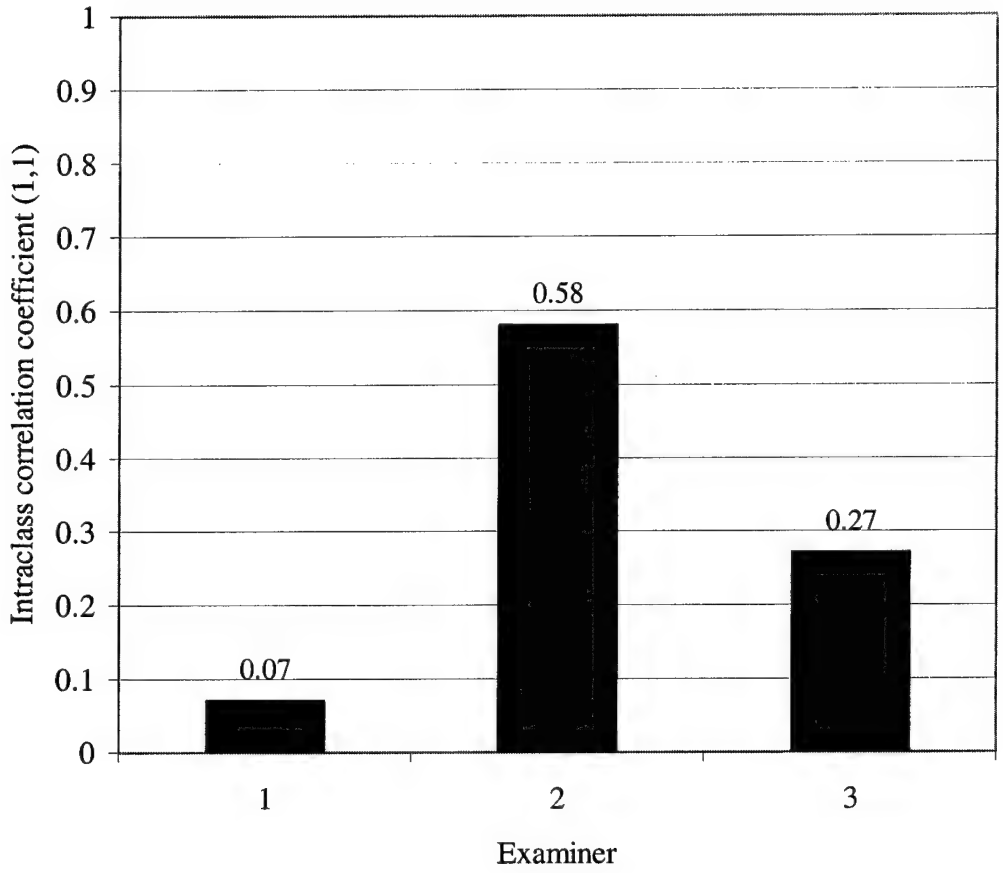

[a] An ICC of 1 would represent complete agreement for an examiner for all viewing sessions.

TABLE VI

Intra-examiner agreement of image quality for each level of compression[a]

Compression	Examiner	ICC (1,1)
1:1	1	0.04
1:1	2	0.5
1:1	3	0.13
1:8	1	0.03
1:8	2	0.59
1:8	3	0.24
1:20	1	0.05
1:20	2	0.57
1:20	3	0.21
1:40	1	0
1:40	2	0.59
1:40	3	0.3
1:60	1	0.23
1:60	2	0.64
1:60	3	0.28
1:80	1	0.04
1:80	2	0.58
1:80	3	0.47

[a] An intraclass correlation coefficient (ICC) of 1 would represent complete agreement by an examiner for all viewing sessions within the corresponding compression ratio. Compression had a significant effect on perceived image quality.

TABLE VII

Inter-examiner agreement in determining image quality at each level of compression[a]

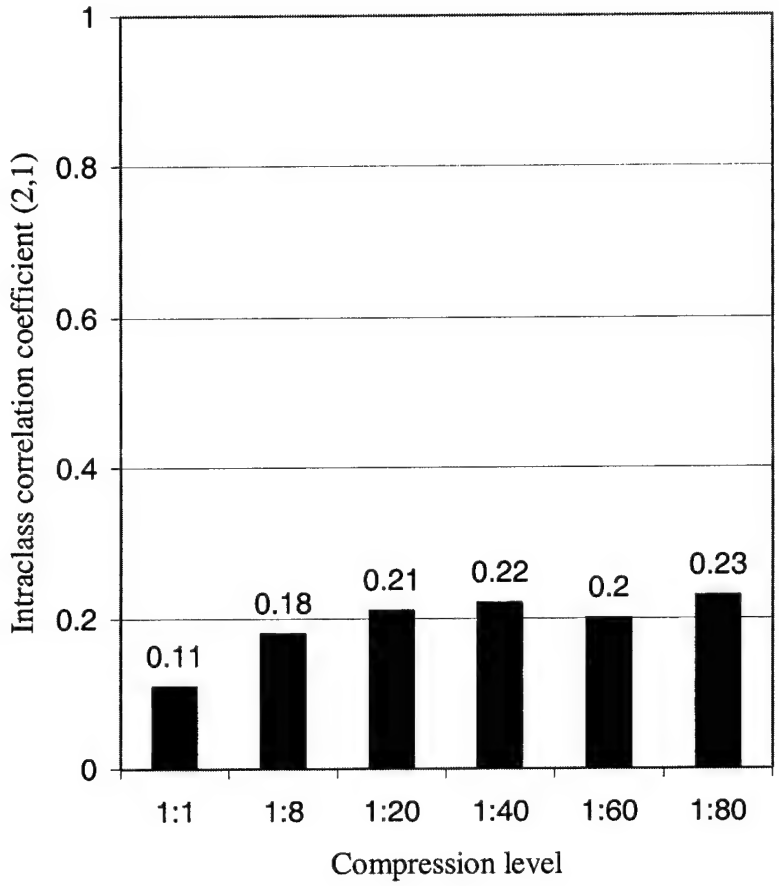

[a] An ICC of 1 would represent complete agreement between the three examiners within the corresponding compression ratio. Compression had a significant effect on perceived image quality.

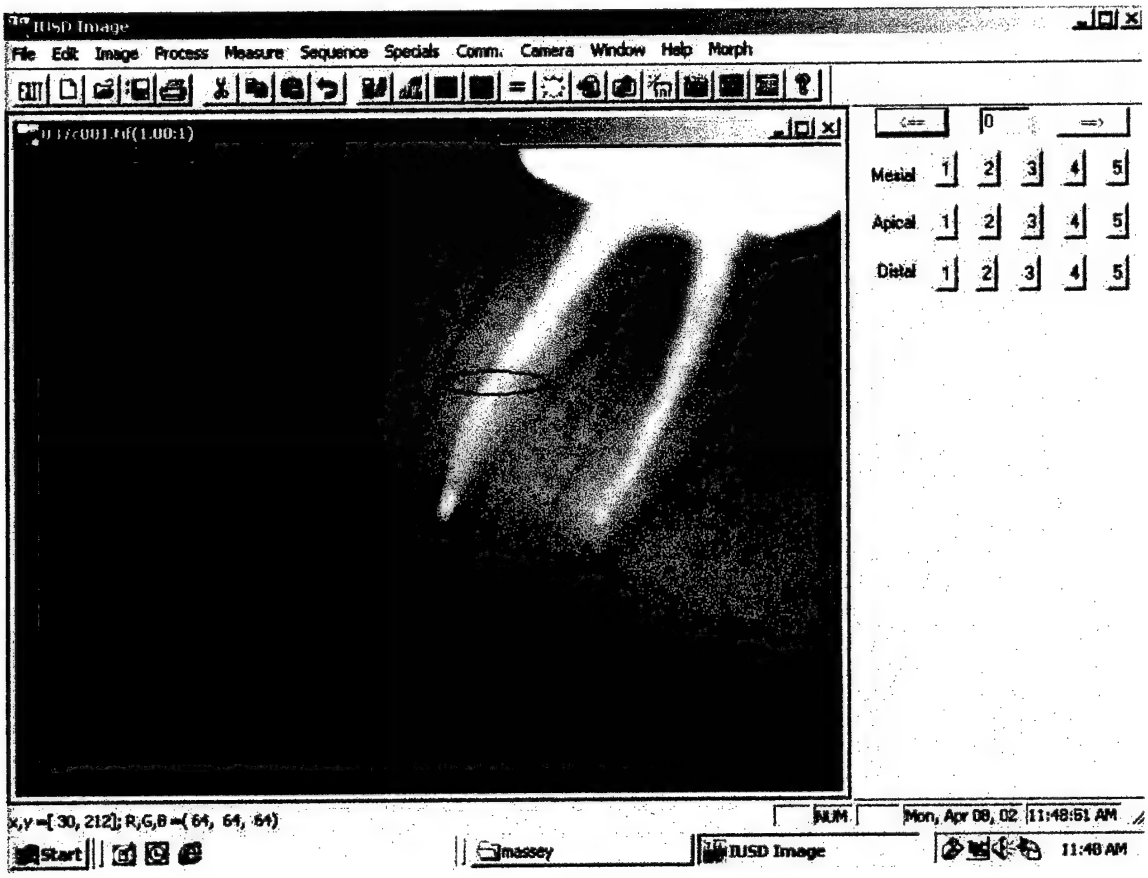

FIGURE 1. Screen display used for image evaluation. Root to be evaluated identified with digital marker.

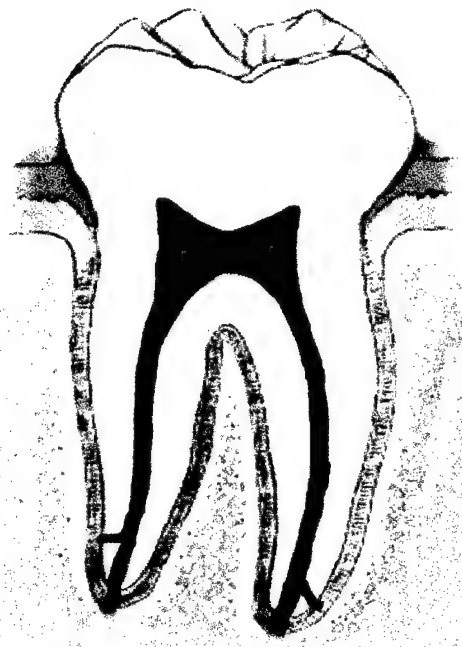

FIGURE 2. Lesion size was determined by the greatest diameter.

FIGURE 3. Test image with no periapical radiolucency associated with root identified by digital marker.

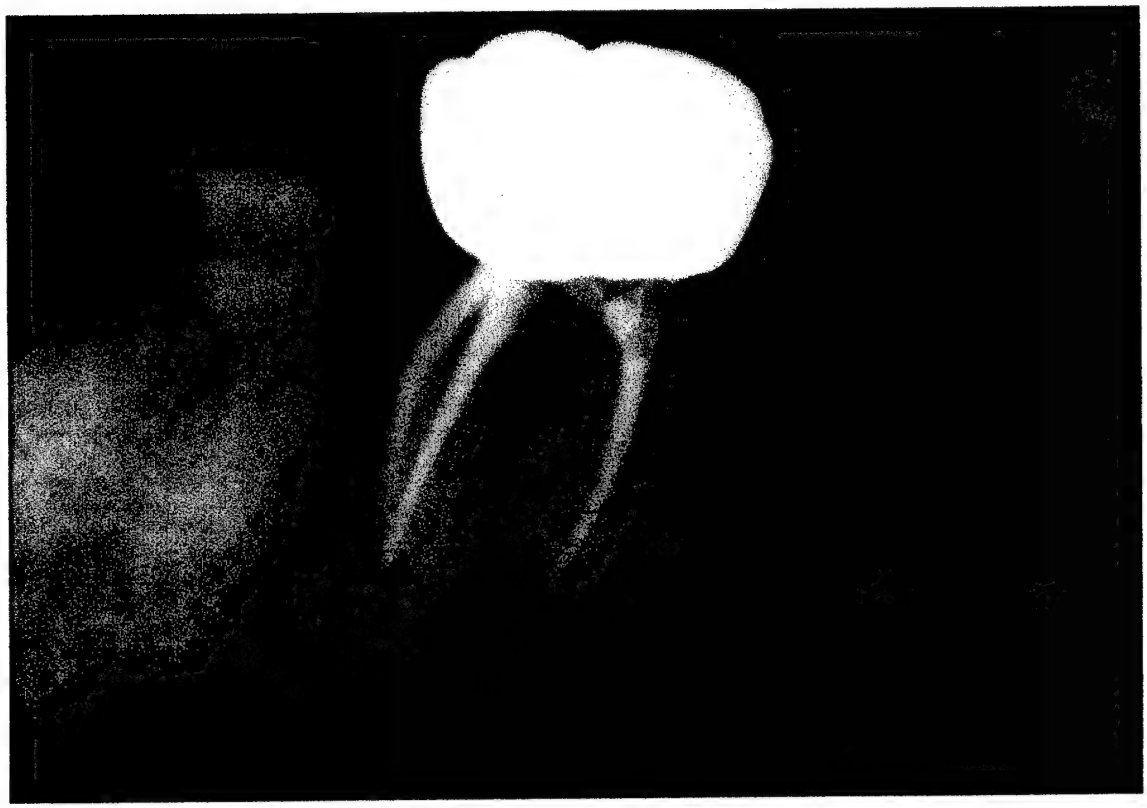

FIGURE 4. Test image with periapical lesion 0.1 mm to 2.0 mm in diameter associated with root identified by digital marker.



FIGURE 5. Test image with periapical lesion 2.1-4.0 mm in diameter associated with root identified by digital marker.



FIGURE 6. Test image with periapical lesion greater than 4.0 mm in diameter associated with root identified by digital marker.

FIGURE 7. Images were viewed under dark room conditions on a 17-inch cathode ray tube monitor, COMPAQ QVISION 210.

FIGURE 8. Test image with compression ratio of 1:1.

FIGURE 9. Test image with compression ratio of 1:8.

FIGURE 10. Test image with compression ratio of 1:20.

FIGURE 11. Test image with compression ratio of 1:40.

FIGURE 12. Test image with compression ratio of 1:60.

FIGURE 13. Test image with compression ratio of 1:80.

DISCUSSION

Inter-examiner agreement in this study for determining the presence of a lesion (ICC of 0.72) yielded greater diagnostic consistency than Zakariasen, Scott and Jensen,[89] Goldman, Pearson and Darzenta,[94] and Reit and Hollander.[95] Zakariasen, Scott and Jensen[89] utilized post-operative and recall radiographs from 330 cases. Four endodontists classified them as success or failure. Inter-examiner agreement was 38 percent. Goldman, Pearson, and Darzenta[94] utilized six examiners (two endodontists, one dental radiologist, and three second-year endodontic residents) to evaluate success or failure of 253 cases by viewing post-operative and recall radiographs. Inter-examiner agreement was 47 percent. Reit and Hollander[95] enlisted three endodontists and three dental radiologists to interpret periapical conditions and quality of root fillings in radiographs of 119 endodontically treated roots. Overall inter-examiner agreement was 39 percent.

The examiners from Reit and Hollender[95] concluded "the large variation noted among clinical and radiographic studies on the results of endodontic therapy could partly be explained by difficulties in defining and maintaining criteria for radiologic evidence of periapical disease." The lesser degree of variance in inter-observer agreement in the present study could be attributed to the design. The evaluation of the periapical area was limited to determining the presence or absence of a lesion in a single image as opposed to comparing postoperative and recall radiographs with different criteria for evaluation. An increase in the number of examiners, images required for an evaluation, and choices possible for an interpretation would decrease inter-examiner agreement.

Intra-examiner agreement in this study for determining the presence of a lesion (ICC of 0.76, 0.77 and 0.89) yielded diagnostic consistency similar to Brynolf,[88]

Zakariasen, Scott and Jensen,[89] Goldman, Pearson and Darzenta[90] and Reit and Hollender.[95] Brynolf[88] utilizing a single examiner and 212 maxillary incisors tested reproducibility of interpretation of the periapical area as normal or as one of five groups representing pathologic changes. One examiner viewing a single periapical film of each incisor had 70-percent intra-observer agreement. One examiner viewing three films projected from differing angles yielded 87-percent intra-observer agreement. Zakariasen, Scott and Jensen[89] utilizing four endodontists determined success or failure of 330 cases from post-operative and recall radiographs. Intra-examiner agreement was 65 percent, 74 percent, 79 percent, and 81 percent for four examiners. Goldman, Pearson and Darzenta,[90] utilizing three of the original six examiners from their previous study of 253 cases, found intra-observer agreement of 74 percent, 79 percent and 80 percent. Reit and Hollender[95] utilizing the six examiners previously discussed found intra-examiner agreement of 68 percent to 82 percent for detection of a radiolucency and 78 percent to 82 percent for identification of a normal periapex. It is of interest to note that while the designs of these studies differed, they resulted in similar intra-examiner agreement.

Lesion size had a significant effect with larger lesions being detected more readily. Patel et al.[101] predicted teeth with larger periapical radiolucencies would be easily detected and excluded them from their study. The results of this study verify their assumption, and in future studies it may be unnecessary to include more advanced lesions. Higher compression ratios could also determine at what level compression would have an effect on lesion detection.

Radiographic appearance of periapical structures is an important component of rendering a clinical diagnosis. Images were determined to have either absence or

presence of a periapical lesion by two panelists who set the gold standard. Only images in which both panelists were in agreement as to the absence or presence of a periapical lesion were included in the study. Requiring agreement by both panelists in establishing the gold standard potentially eliminated periapical lesions that were not readily distinguished. While this may have introduced bias, it was determined to be the best option for confirming the presence of a periapical radiolucency without histologic verification.

Accuracy was compromised without histologic verification of a periapical lesion. This would have required invasive procedures not required for initial treatment. Secondly, histologic verification of a periapical radiolucency is certainly not the clinical norm.

It was determined that compression did not have a significant effect on detection of a lesion. However, compression did have a significant effect on perceived image quality beginning at the 1:40 ratio. Ishigaki et al.[84] evaluated irreversible image compression for chest images with computed tomography. One original and five reconstructed images with compression ratios of 1:3, 1:6, 1:13, 1:19 and 1:31 were ranked according to quality by six radiologists. The acceptable upper limit of the compression ratio was determined to be 1:19. To assess the ability to detect the presence or absence of nodules and linear shadows, 30 plain chest computed radiographic images were compressed with ratios of 1:5, 1:10, 1:20 and 1:25. It was determined that a compression ratio of 1:20 was the upper limit for acceptable compression ratios on chest computed radiography images without sacrificing the ability to detect nodules and linear shadows. Lesion detection was possible at higher compression ratios in the present study

but based on the findings of Ishigaki et al.,[84] subtle radiographic changes indicating either possible progression or resolution of a periapical lesion might not be detected. The results of the current study as well as those by Ishigaki et al.[84] indicate a compression ratio of 1:20 would allow storage of images without a significant effect on perceived image quality.

Inter and intra-examiner agreement for image quality were also recorded. Both inter and intra-examiner agreement were less consistent when compared with detecting the presence of a lesion. This could be explained in part, because the perception of image quality is a more subjective judgment. A large variance in overall intra-examiner agreement for determining image quality (Table 2) was noted with Examiner 1 having an ICC of 0.07 compared with a score of 0.58 for Examiner 2, and 0.27 for Examiner 3. Examiner 1 scored nearly every image in the study with an identical score for image quality. The ICC does not directly reflect agreement but rather shows variability of scoring within each image and between images. Due to the low degree of overall variance the corresponding ICC value was low. Oral and written instructions for determining image quality along with examples from each of the five categories of image quality were provided for each examiner prior to viewing the images. The cause for examiner 1 scoring nearly every image with an identical image quality score is unknown to the author.

SUMMARY AND CONCLUSIONS

The purpose of this study was to ascertain the level of JPEG 2000 compression that significantly compromised an evaluators' ability to detect the presence or absence of periapical radiolucencies of varied size. The perceived quality of the image was also evaluated.

A total of 600 images were randomized and viewed three times by three second-year endodontic residents. Compression ratios represented were 1:1, 1:8, 1:20, 1:40, 1:60 and 1:80 (Figures 8-13). Images with no lesion present, lesions of 0.1 mm to 2.0 mm in diameter, 2.1 mm to 4.0 mm in diameter and greater than 4.0 mm in diameter were utilized in the study. Absence, presence, and diameter of lesions were determined by two panelists who set the gold standard for lesion presence. Examiners were asked to evaluate the periapical area identified in each image and classify their readings according to a lesion presence rating scale as: 1 = Definitely present; 2 = Probably present; 3 = Uncertain; 4 = Probably not present; 5 = Definitely not present. Perceived image quality was also recorded utilizing an image quality rating scale as: 1 = Excellent quality; 2 = Above average quality; 3 = Average quality; 4 = Below average quality; 5 = Poor quality.

Inter- and intra-examiner agreement for the presence of a lesion and image quality were assessed using intraclass correlation coefficients (ICC). The ICC were calculated for each of the six compression ratios. Calculations were also accomplished for each of the four lesion sizes within each compression ratio.

To determine if compression had an effect on determining the presence of a lesion and perceived image quality, a generalized linear mixed model was fit to each of these variables. Compression, lesion size and the interaction between compression and size were fixed effects in the model. The random effects included the examiner and the

image. Comparisons were made between different compression ratios and lesion sizes. The Sidak multiple comparison adjustment method was used to control the overall confidence level at 95 percent. A statistically significant difference existed if the p-value was less than 0.05.

Intra-examiner agreement for the presence of a lesion detection ranged in ICC value from 0.70 to 0.75. Presence of a lesion detection was significantly affected by lesion size as larger lesions were detected with greater consistency. The effects of compression and interaction between lesion size and compression were not significant. Overall, there were no significant differences in the presence of a lesion score between compression ratios.

It was determined in the present study that compression ratios up to 1:80 did not have a significant effect on detection of lesion presence. Compression did have a significant effect on perceived image quality beginning at the 1:40 ratio. Based on the findings of Ishigaki et al.[84]subtle radiographic changes indicating either possible progression or resolution of a periapical lesion might not be detected. A compression ratio of 1:20 would allow storage of images without a significant effect on perceived image quality.

The ICC for intra-examiner agreement of perceived image quality ranged in value from 0.07 to 0.58. The ICC for inter-examiner agreement of perceived image quality ranged in value from 0.11 to 0.23. Compression and lesion size had a significant effect on perceived image quality. The interaction between compression and lesion size did not have a significant effect on perceived image quality.

REFERENCES

1. Barbat J, Messer H. Detectability of artificial periapical lesions using direct digital and conventional radiography. J Endodont 1998; 24: 837-42.

2. Kullendorf B, Nilsson M, Rohlin M. Diagnostic accuracy of direct dental radiography for the detection of periapical bone lesions. Oral Surg Oral Med Oral Pathol 1996; 82: 344-50.

3. Tirrel B, Miles D, Brown C, Legan J. Interpretation of chemically created lesions using direct digital imaging. J Endodont 1996; 22: 74-8.

4. Paurazas SB, Geist JR, Pink FE, Hoen MM, Steiman HR. Comparison of diagnostic accuracy of digital imaging using ccd and cmos-aps sensors with E-speed film in the detection of periapical bony lesions. Oral Surg Oral Med Oral Pathol 2000; 89: 356-62.

5. Brooks SL, Miles DA. Advances in diagnostic imaging in dentistry. Dent Clin North Am 1993; 37: 91-111.

6. MacMahon H. Data compression: effect on diagnostic accuracy in digital chest radiography (Pt 1). Radiol 1991; 178: 175-9.

7. Kajiwara K. JPEG compression for pacs. Computer Methods Programs Biomed 1992; 37: 343-51.

8. Glenner RA. Eighty years of dental radiography. J Am Dent Assoc 1975; 90: 549-64.

9. McCormack FW. A plea for a standardized technique for oral radiography, with an illustrated classification of findings and their verified interpretations. J Dent Res 1920; 2: 467-89.

10. Goaz PW, White SC. Oral radiology: principles and interpretation. 3rd ed. St Louis: CV Mosby, 1994: 1-23.

11. LeMaster C. A modification of technique for radiographing upper molars. J Nat Dent Assoc 1921; 8: 328.

12. Liebman EA. The management of pulpless teeth which have been previously treated. Dent Cosmos 1936; 78: 1152-60.

13. Sweet AP. The legal aspect of dental roentgenograms. J Am Dent Assoc 1938; 25: 1679-87.

14. Goldman HM, Millsap JS, Brenman HS. Origin of registration of the architectural pattern, the lamina dura, and the alveolar crest in the dental radiograph. Oral Surg Oral Med Oral Pathol 1957; 10: 749-58.

15. Bender IB, Seltzer S. Roentgenographic and direct observation of experimental bone lesions. (Pt 1). J Am Dent Assoc 1961; 62: 152-60.

16. Manson JD. The lamina dura. Oral Surg Oral Med Oral Pathol 1963; 16: 432-8.

17. Kilpinen E, Hakala PE. Reproduction of the lamina dura in dental radiographs. Dentomaxillofac Radiol 1978; 7: 51-4.

18. Ingram F. Radiology of the teeth and jaws. London: Arnold, 1950: 56-66.

19. Hutchinson A. Dental and oral x-ray diagnosis. Edingurgh: Livingstone, 1954: 45-55.

20. Stafne E. Oral roentgenographic diagnosis. Philadelphia: Saunders, 1958: 70-5.

21. Ennis L, Berry H. Dental roentgenology. London: Kimpton, 1959: 351-62.

22. Kakehashi S, Stanley HR, Fitzgerald RJ. The effects of surgical exposures of dental pulps in germ-free and conventional laboratory rats. Oral Surg Oral Med Oral Pathol 1965; 20: 340-9.

23. Trowbridge HO. Immunological aspects of chronic inflammation and repair. J Endodont 1990; 16: 54-61.

24. Eberhard J, Plagmann HC. Changes in the periodontal membrane due to apical periodontitis. J Endodont 1999; 25: 486-9.

25. Lin SK et al. Immunolocalization of macrophages and transforming growth factor-$Beta_1$, in induced rat periapical lesions. J Endodont 2000; 26: 335-40.

26. Zuolo ML et al. Identification of GM3 as a marker of therapy-resistant periradicular lesions. J Endodont 2001; 27: 107-12.

27. Bender IB, Seltzer S, Soltanoff W. Endodontic success- a reappraisal of criteria. (Pt 2). Oral Surg Oral Med Oral Pathol 1966; 22: 790-802.

28. Ramadan AE, Mitchell DF. A roentgenographic study of experimental bone destruction. Oral Surg Oral Med Oral Pathol 1962; 15: 934-43.

29. Regan JE, Mitchell DF. Evaluation of periapical radiolucencies found in cadavers. J Am Dent Assoc 1963; 66: 529-33.

30. Brynolf I. Roentgenologic periapical diagnosis. One, two or more roentgenograms. Swed Dent J 1970; 63: 345-50.

31. Poyton HG, Pharoah MJ. Oral radiology. 2nd ed. Philadelphia: B.C. Decker Inc., 1989: 12-6.

32. Weissman DD, Solokowski FJ. Comparative dosimetry of intraoral periapical radiography. Oral Surg Oral Med Oral Pathol 1970; 29: 376-86.

33. Nolan WE. Radiation hazards to the patient from oral roentgenography. J Am Dent Assoc 1953; 47: 681-4.

34. Richards AG. Quality of an x-ray beam. Oral Surg Oral Med Oral Pathol 1964; 17: 739-44.

35. Alcox RW, Jamison WR. Patient exposures from intraoral radiographic examinations. J Am Dent Assoc 1974; 88: 568-79.

36. Welander U, Wickman G. The relationship between the integral dose and the focus to object distance in dental radiography. Dentomaxillofacial Radiol 1977; 6: 83-7.

37. Kasle MJ, Langlais RP. Basic principles of oral radiography. Volume 4. Philadelphia: WB Saunders, 1981: 9-15.

38. Fitzgerald GM. Dental roentgenography (Pt 1). An investigation in adumbration, or the factors that control geometric unsharpness. J Am Dent Assoc 1947; 34: 1-20.

39. Updegrave WJ. Simplified and standardized bisecting angle technique for dental radiography. J Am Dent Assoc 1967; 75: 6.

40. Updegrave WJ. The paralleling extension-cone technique in intraoral dental radiography. Oral Surg Oral Med Oral Pathol 1951; 4: 1250-61.

41. Tamse A, Kaffe I. Zygomatic arch interference with correct radiographic diagnosis in maxillary molar endodontics. Oral Surg Oral Med Oral Pathol 1980; 50: 563-5.

42. Wengraf AM. Angulation in periapical radiography. British Dent J 1965; 118: 528-31.

43. Bender IB, Seltzer S, Soltanoff W. Endodontic success- a reappraisal of criteria. (Pt 1). Oral Surg Oral Med Oral Pathol 1966;22: 780-9.

44. Walton RE. Endodontic radiographic technique. Dent Radiogr Photogr 1973; 46: 51.

45. Thunty KH. Radiographic illusions due to faulty angulations. Dent Radiogr Photogr 1978; 51: 1-7.

46. Updegrave WJ. Right angle dental radiography with the conventional short tube. Gen Dent 1981; 3: 220-4.

47. Barr JH, Gron P. Palate contour as a limiting factor in intraoral x-ray technique. Oral Surg Oral Med Oral Pathol 1959; 12: 459-72.

48. Manson-Hing LR. Kilovolt peak and the visibility of lamina dura breaks. Oral Surg Oral Med Oral Pathol 1971; 31: 268-73.

49. Thunty KH, Manson-Hing LR. Effects of mAs and kVp on resolution and on image contrast. Oral Surg Oral Med Oral Pathol 1978; 46: 454-61.

50. Boyle WS, Smith GE. Charge coupled semiconductor devices. Bell Systems Technical J, April 1970L 587-93.

51. Photometrics Ltd. Charge-coupled devices for quantitative electronic imaging. Tuscon:1991.

52. Miles DA. Imaging using solid state detectors. Dent Clin N Amer 1993; 37: 531-40.

53. Farman AG. Basic technical properties of a system for direct acquisition of digital intraoral radiographs. Oral Surg Oral Med Oral Pathol 1993; 75: 506-16.

54. Wenzel A, Gotfredsen E, Borg E, Grondahl HG. Impact of lossy image compression on accuracy of caries detection in digital images taken with a storage phosphor system. Oral Surg Oral Med Oral Pathol 1996; 81: 351-5.

55. Southard T. Radiographic image storage via laser optical disk technology. Oral Surg Oral Med Oral Pathol 1985; 60: 436-9.

56. Brandt T. Archiving of digitized dental radiographs for optimal office organization. Dentomaxillofac Radiol 1992; 21: 226.

57. Almgren M. The dental radiology office of the future: my vision. Dentomaxillofac Radiol 1992; 21: 226-7.

58. Smathers R, Brody W. Digital radiography: current and future trends. Br J Radiol 1985; 58: 285-306.

59. Bauman R, Lodwick M, Taveras O. The digital computer in medical imaging: a critical review. Radiology 1984; 153: 73-5.

60. Skov S, Sewerin I. Prototype system for archiving and transmitting digitized radiographs. Dentomaxillofac Radiol 1992; 22; 99-101.

61. Wenzel A. Effect of varying gray –scale resolution for detectability of bone lesions in intraoral radiographs digitized for teletransmission. Scand J Dent Res 11987; 95: 483-92.

62. Cannon T, Hunt B. Image processing by computer. Sci Am 1981; 245: 136-45.

63. Bruder GA, Casale J, Goren A, Friedman S. Alteration of computer dental radiography images. J of Endodont 1999; 25: 275-6.

64. Lasher J, Blumhardt R, Lancaster J. The digital computer: the role of functional imaging in radiology. Radiology 1984; 153: 69-72.

65. Ram G. Optimizing of ionizing radiation usage in medical imaging by means of image enhancement techniques. Med Phys 1982; 9: 733-7.

66. White SC, Yoon DC. Comparative performance of digital and conventional images for detecting proximal surface caries. Dentomaxillofac Radiol 1997; 26: 32-8.

67. Welander U, Nelvig P, Tronje G. Basic technical properties of a system for direct acquisition of digital intraoral radiographs. Dentomaxillofac Radiol 1992; 21: 222.

68. Mouyen F, Benz C, Sonnabend E, Lodter JP. Preservation and physical evaluation of RadioVisioGraphy. Oral Surg Oral Med Oral Pathol 1989; 68: 238-42.

69. Soh G, Loh FC, Chong YH. Radiation dosage of a dental imaging system. Quintessence Int 1993; 24: 189-91.

70. Shearer AC, Horner K, Wilson NHF. Radiovisiography for imaging root canals: an in vitro comparison with conventional radiography. Quintessence Int 1990; 21: 789-94.

71. Leddy BJ, Miles DA, Newton CW, Brown CE. Interpretation of endodontic file lengths using Radiovisiography. J Endodont 1994; 20: 542-5.

72. Yokota ET, Miles DA, Newton CW, Brown CE. Interpretation of periapical lesions using Radiovisiography. J Endodont 1994; 20: 490-4.

73. Nelvig P, Wing K, Welander U. Sens-A-Ray: a new system for direct intraoral radiography. Oral Surg Oral Med Oral Pathol 1992; 74: 818-23.

74. Farman AG. Direct digital radiography for the detection of periodontal bone lesions. Oral Surg Oral Med Oral Pathol 1992; 74: 652-60.

75. McDonnell D, Price C. An evaluation of the sens-a ray digital dental imaging system. Dentomaxillofac Radiol 1993; 22: 121-6.

76. Molteni, R. Direct digital dental x-ray imaging with visualix/vixa, Oral Surg Oral Med Oral Pathol 1993; 76: 235-43.

77. Scarfe W, Farman A, Kelly M. Flash Dent: an alternative charge-coupled device/scintillator-based direct digital intraoral radiographic system. Dentomaxillofac Radiol 1994; 23: 11-7.

78. Nelvig P, Wing KW. Sens-A-Ray: a new system for direct digital imaging. Oral Surg Oral Med Oral Pathol 1992; 74: 818-23.

79. Gillespy T, Rowberg AH. Displaying radiologic images on personal computers: image storage and compression. (Pt 1). J Digital Imaging 1993; 6: 197-204.

80. Bramble JM. Comparison of information preserving and information-losing data-compression algorithms for CT images. Radiol 1989; 170: 453-5.

81. Good WF, Maitz GS, Gur D. Joint photographic experts group (jpeg) compatible data compression of mammograms. J Digital Imaging1994; 7: 123-32.

82. Clunie DA. Lossless compression of grayscale medical images-effectiveness of traditional and state of the art approaches. In: Blaine G, Siegel E, eds. PACS design and evaluation: engineering and clinical issues, (Feb 2000) Proc SPIE. Vol 3980; Feb 2000.

83. Gilespy T, Rowberg AH. Displaying radiologic images on personal computers. (Pt 2). J Digital Imaging 1994; 7: 1-12.

84. Ishigaki T, Sakuma S, Ikeda M, Itoh Y, Suzuki M, Iwai S. Clinical evaluation of irreversible image compression: analysis of chest imaging with computed radiography. Radiol 1990; 175: 739-43.

85. MacMahon H. Data compression: effect on diagnostic accuracy in digital chest radiography. Radiol 1991; 178: 175-9.

86. Cosman PC, Davidson HC, Bergin CJ, et al. Thoracic CT images: effect of lossy image compression on diagnostic accuracy. (Pt 1). Radiol 1994; 190: 517-24.

87. Garland LH. On the reliability of roentgen survey procedures. Am J Roentgenol 1950; 64: 32-41.

88. Brynolf I. Roentgenologic periapical diagnosis. (Pt 1). Reproducibility of interpretation. Swed Dent J 1970; 63: 339-44.

89. Zakariasen KL, Scott DA, Jensen JR. Endodontic recall radiographs: how reliable is our interpretation of endodontic success or failure and what factors affect our reliability. Oral Surg Oral Med Oral Pathol 1974; 57: 343-7.

90. Goldman M, Pearson AH, Darzenta N. Reliability of radiographic interpretations. Oral Surg Oral Med Oral Pathol 1974; 38: 287-93.

91. Haugejorden O, Slack GL. A study of intra-examiner error associated with recording of radiographic caries at different diagnostic levels. Acta Odontol Scand 1975; 33: 169-81.

92. Garland L. Studies on the accuracy of diagnostic procedures. Am J Roentgenol 1959; 82: 25-35.

93. Manson-Hing LR. Variations in the interpretation of periapical radiolucencies. Oral Surg Oral Med Oral Pathol 1975; 40: 414-22.

94. Goldman M, Pearson AH, Darzenta N. Endodontic success-who's reading the radiograph? Oral Surg Oral Med Oral Pathol 1972; 33: 432-7.

95. Reit C, Hollender L. Radiologic evaluation of endodontic therapy and the influence of observer variation. Scand J Dent Res 1983; 91: 205-12.

96. Kaffe I, Gratt BM. Variations in the radiographic interpretation of the periapical dental region. J Endodont 1988; 14: 330-5.

97. Grondahl HG. Some factors influencing observer performance in radiographic caries diagnosis. Swed Dent J 1979; 3: 157-72.

98. Eckerbom M, Andersson JE, Magnusson T. Interobserver variation in radiographic examination of endodontic variables. Endod Dent Traumatol 1986; 2: 243-6.

99. Valachovic RW, Douglass CW, Berkey CS, McNeil BJ, Chauncey HH. Examiner reliability in dental radiography. J Dent Res 1986; 65: 432-6.

100. Herman PG, Hessel SJ. Accuracy and its relationship to experience in the interpretation of chest radiographs. Invest Radiol 1975; 10: 62-7.

101. Patel N, Rushton VE, MacFarlane TV, Horner K. The influence of viewing conditions on radiologic diagnosis of periapical inflammation. British Dent J 2000; 189: 40-2.

102. Antrim DD. Reading the radiograph: a comparison of viewing techniques. J Endodont 1983; 9: 502-5.

103. Welander U, McDavid WD, Higgins NM, Morris CR. The effect of viewing conditions on the perceptibility of radiographic details. Oral Surg Oral Med Oral Pathol 1983; 56: 651-4.

104. Brynolf I. Roentgenologic periapical diagnosis. (Pt 4). When is one roentgenogram not sufficient? Swed Dent J 1970; 63: 415-23.

105. Brynolf I. Roentgenologic periapical diagnosis. (Pt 3). The more roentgenograms-the better the information? Swed Dent J 1970; 63: 409-13.

106. Goldstein IL, Mobley WH, Chellemi SJ. The observer process in the visual interpretation of radiographs. J Dent Educ 1971; 35: 485-91.

107. Jensen TH. Image perception in dental radiography. Dentomaxillofacial Radiol 1980; 9: 37-40.

108. Tidmarsh BG. Radiographic interpretation of endodontic lesions-a shadow of reality. Int Endodont J 1987; 37: 10-5.

109. Kullendorff B, Petersson K, Rohlin M. Direct digital radiography for the detection of periapical bone lesions: a clinical study. Endodont Dent Traumatol 1997; 13: 183-9

ABSTRACT

JPEG 2000 COMPRESSION OF DIRECT DIGITAL IMAGING: ITS EFFECTS ON DETECTION OF PERIAPICAL RADIOLUCENCIES AND PERCEIVED IMAGE QUALITY

by
Mark A. Massey

Indiana University School of Dentistry
Indianapolis, Indiana

A disadvantage of direct digital images (DDI) is the number of bytes required for storage. JPEG 2000 is a recent data compression technique designed to address the problem, but significant image deterioration occurs at high compression ratios. There is currently no consensus as to the acceptable level of compression for DDI in dentistry. The purpose of this study was to evaluate JPEG 2000 compression of DDI and its effect on the detection of periapical radiolucencies and perceived image quality.

One hundred images were selected from the DDI database (Schick Technologies Inc.) located in the Endodontic Graduate Clinic at Indiana University School of Dentistry. Images were subjected to the following compression ratios: 1:1, 1:8, 1:20, 1:40, 1:60, 1:80. Images were randomized and viewed by three second-year endodontic residents. Randomized images were viewed three times by each evaluator under dark room

conditions. Evaluators were asked to record the presence or absence of a lesion as well as perceived image quality.

To determine if compression had an effect on determining lesion presence and perceived image quality, a general linear mixed model was used. Compression, lesion size, and the interaction between compression and size were fixed effects in the model. The random effects were the examiner and image. Inter and intra-examiner agreement for presence of a lesion and perceived image quality were assessed using intraclass correlation coefficients (ICC).

Lesion detection was significantly affected by lesion size. The effects of compression and the interaction between size and compression were not significant for lesion detection. Average intra-examiner agreement for lesion detection had an ICC of 0.81. Average inter-examiner agreement for lesion detection had an ICC of 0.72.

Compression and lesion size were significant effects on perceived image quality, but the interaction between these effects was not significant. Average intra-examiner agreement for perceived image quality had an ICC of 0.31. Average inter-examiner agreement for perceived image quality had an ICC of 0.19.

CURRICULUM VITAE

Mark Allen Massey

October 16, 1968	Born in Springfield, MO
August 31, 1991	BA in Biology William Jewell College Liberty, MO
May 5, 1995	DDS University of Missouri- Kansas City School of Dentistry Kansas City, MO
July 29, 1995 to August 2, 1996	AEGD Residency Langley AFB Hampton, VA
August 1996 to August 1998	General Dental Officer Seymour Johnson AFB Goldsboro, NC
August 1998 to July 2000	General Dental Officer Andersen AFB Yigo GU
July 2000 to June 2002	MSD Program, Endodontics Indiana University School of Dentistry Indianapolis, IN

Professional Organizations

American Association of Endodontics
American Dental Association
Association of Military Surgeons of the United States